



REVIEW ARTICLE



Consensus guideline for the diagnosis and management of mannose phosphate isomerase-congenital disorder of glycosylation

Anna Čechová¹ | Ruqaiyah Altassan² | Delphine Borgel³ |
Arnaud Bruneel^{4,5} | Joana Correia⁶ | Muriel Girard⁷ | Annie Harroche⁸ |
Beata Kiec-Wilk⁹ | Klaus Mohnike¹⁰ | Tiffany Pascreau³ | Łukasz Pawliński⁹ |
Silvia Radenkovic^{11,12} | Sandrine Vuillaumier-Barrot^{4,13} |
Luis Aldamiz-Echevarria¹⁴ | Maria Luz Couce¹⁵ | Esmeralda G. Martins⁶ |
Dulce Quelhas¹⁶ | Eva Morava¹⁷ | Pascale de Lonlay¹⁸ | Peter Witters^{19,20} |
Tomáš Honzík¹

¹Department of Pediatrics and Adolescent Medicine, First Faculty of Medicine, Charles University and General University Hospital in Prague, Prague, Czech Republic

²Medical Genetic Department, King Faisal Specialist Hospital and Research Center, Alfaisal University, Riyadh, Saudi Arabia

³Service d'Hématologie Biologique, Hôpital Necker, Assistance Publique-Hôpitaux de Paris, Université Paris-Saclay, Paris, France

⁴Department of Biochemistry, Assistance Publique-Hôpitaux de Paris, Bichat Hospital, Paris, France

⁵INSERM UMR1193, Mécanismes Cellulaires et Moléculaires de l'Adaptation au Stress et Cancérogenèse, Université Paris-Saclay, Châtenay-Malabry, France

⁶Centro de Referência Doenças Hereditárias do Metabolismo - Centro Hospitalar Universitário do Porto (CHUP), Porto, Portugal

⁷Reference Center of Liver Diseases, Necker Hospital, Assistance Publique-Hôpitaux de Paris, University Paris Descartes, Paris, France

⁸Hemophilia Care Centre, Hematology Unit, Hôpital Necker, Assistance Publique-Hôpitaux de Paris, Paris, France

⁹Department of Metabolic Diseases JUMC, Krakow and NSSU University Hospital, Krakow, Poland

¹⁰Department of Paediatrics, Otto-von-Guericke University, Magdeburg, Germany

¹¹Metabolomics Expertise Center, CCB-VIB, Leuven, Belgium

¹²Department of Clinical Genomics and Laboratory of Medical Pathology, Mayo Clinic, Rochester, Minnesota

¹³INSERM U1149, Centre de Recherche sur l'Inflammation (CRI) and Université Paris 7 Denis Diderot, Paris, France

¹⁴Group of Metabolism, Biocruces Bizkaia Health Research Institute, Linked Clinical Group of Rare Diseases CIBER (CIBERER), Barakaldo, Spain

¹⁵Department of Pediatrics, Congenital Metabolic Unit, University Clinical Hospital of Santiago, University of Santiago de Compostela, IDIS, CIBERER, MetabERN, Santiago de Compostela, Spain

Abbreviations: A1AT, alpha-1 antitrypsin; AGA, aspartylglucosaminidase activity; ALP, alkaline phosphatase; ALS, acid-labile subunit; AT, antithrombin; CE, capillary electrophoresis; CDG, congenital disorders of glycosylation; CDT%, carbohydrate deficient transferrin percentage; CT, computer tomography; DD, developmental delay; ESI-MS, electrospray ionisation-mass spectrometry; FSH, follicle-stimulating hormone; FT4, free thyroxine; FXI, factor XI; GGT, gamma-glutamyl transferase; HbA1C, glycated hemoglobin; ICAM-1, intercellular adhesion molecule 1; IGF, insulin-like growth factor; IGF1BP, IGF-binding protein; GH, growth hormone; G6PD, glucose 6-phosphate dehydrogenase; HH, hyperinsulinaemic hypoglycaemia; HPLC, high performance liquid chromatography; LC-MS-MS, liquid chromatography with tandem mass spectrometry; LCHAD, long-chain 3-hydroxyacyl-CoA dehydrogenase; LH, luteinizing hormone; LMWH, low-molecular-weight heparin; MALDI-TOF MS, matrix-assisted laser desorption/ionisation-time-of-flight mass spectrometry; MPI, mannose phosphate isomerase; MRI, magnetic resonance imaging; PC, protein C; PGI, phosphoglucose isomerase; PGM, phosphoglucomutase; PLE, protein-losing enteropathy; PMI, phosphomannose isomerase; PMM2, phosphomannomutase 2; PS, protein S; PTH, parathyroid hormone; SDS-PAGE, sodium dodecyl sulphate-polyacrylamide gel electrophoresis; TBG, thyroxine-binding globulin; TIEF, transferrin isoelectric focusing; Trf, transferrin; TSH, thyroid-stimulating hormone; UFH, unfractionated heparin; VKA, vitamin K antagonist.

Communicating Editor: Saadet Mercimek-Andrews

¹⁶Centro de Genética Médica Jacinto de Magalhães, Centro de Referência Doenças Hereditárias do Metabolismo - Centro Hospitalar Universitário do Porto (CHUP), Unit for Multidisciplinary Research in Biomedicine, ICBAS, UP, Porto, Portugal

¹⁷Department of Clinical Genomics, Mayo Clinic, Rochester, Minnesota

¹⁸Reference Center of Inherited Metabolic Diseases, Necker Hospital, APHP, University Paris Descartes, Filière G2M, MetabERN, Paris, France

¹⁹Department of Paediatrics and Metabolic Center, University Hospitals Leuven, Leuven, Belgium

²⁰Department of Development and Regeneration, KU Leuven, Leuven, Belgium

Correspondence

Pascale de Lonlay, Reference Center of Inherited Metabolic Diseases, Necker Hospital, APHP, 149 rue de Sèvres, 75743, University Paris Descartes, Filière G2M, MetabERN, Paris, France.
Email: pdelonlay@neuf.fr

Peter Witters, Department of Paediatrics and Metabolic Center, University Hospitals Leuven, 3000 Leuven, Belgium.
Email: peter.witters@uzleuven.be

Tomáš Honzík, Department of Pediatrics and Adolescent Medicine, First Faculty of Medicine, Charles University and General University Hospital in Prague, Ke Karlovu 2, Prague 2, 128 08, Czech Republic.
Email: tomas.honzik@vfn.cz

Funding information

Clinical Research Foundation of University Hospitals Leuven; National Institutes of Health, Grant/Award Number: 1 U54 NS115198-01 PI; European Union's Horizon 2020 Research and Innovation Program, Grant/Award Number: 643578; Ministry of Education Youth and Sports of Czech Republic, Grant/Award Number: 8F19002; Progress Q26/LF1 Programs of the Charles University; UNCE 204064; General University Hospital in Prague, Grant/Award Number: RVO-VFN 64165; Ministry of Health of the Czech Republic, Grant/Award Number: MZ CR AZV 16-31932A; European Reference Network for Hereditary Metabolic Diseases, Grant/Award Number: 739543

Communicating Editor: Saadet Mercimek-Andrews

Abstract

Mannose phosphate isomerase-congenital disorder of glycosylation (MPI-CDG) deficiency is a rare subtype of congenital disorders of protein *N*-glycosylation. It is characterised by deficiency of MPI caused by pathogenic variants in *MPI* gene. The manifestation of MPI-CDG is different from other CDGs as the patients suffer dominantly from gastrointestinal and hepatic involvement whereas they usually do not present intellectual disability or neurological impairment. It is also one of the few treatable subtypes of CDGs with proven effect of oral mannose. This article covers a complex review of the literature and recommendations for the management of MPI-CDG with an emphasis on the clinical aspect of the disease. A team of international experts elaborated summaries and recommendations for diagnostics, differential diagnosis, management, and treatment of each system/organ involvement based on evidence-based data and experts' opinions. Those guidelines also reveal more questions about MPI-CDG which need to be further studied.

KEYWORDS

AT deficiency, guidelines, hepatic fibrosis, hyperinsulinaemic hypoglycaemia, mannose phosphate isomerase, MPI-CDG, protein-losing enteropathy

1 | INTRODUCTION

Mannose phosphate isomerase-congenital disorder of glycosylation (MPI-CDG, formerly CDG-Ib or also phosphomannose isomerase deficiency, mannose phosphate isomerase deficiency, Saguenay-Lac Saint-Jean syndrome, protein-losing enteropathy (PLE)-hepatic fibrosis

syndrome) (OMIM 602579) is a disorder of protein *N*-glycosylation. It is characterised by deficiency of MPI caused by pathogenic variants in *MPI* gene on the long arm of chromosome 15. The manifestation of MPI-CDG is different from other CDGs as the patients suffer dominantly from hypoglycaemia, gastrointestinal, and hepatic involvement whereas they usually do not present intellectual disability

or neurological impairment. It is also one of the few treatable subtypes of CDGs with proven effect of oral mannose.

2 | PREVALENCE

MPI-CDG is a rare autosomal recessive disorder with only 35 patients described so far. The prevalence is not known.

3 | HISTORY

First two patients with congenital hepatic fibrosis later diagnosed with MPI-CDG were reported in 1980.¹ Pelletier et al described a new genetical syndrome in four infants presenting with intractable diarrhoea, vomiting, anasarca, hepatomegaly, hypoglycaemia, and malnutrition within the first 3 months of life, all the children came from Lac St. Jean region.² It was not until 1998, when Niehues et al discovered MPI deficiency in a 6-year-old boy with PLE, vomiting, and coagulation disorder, found one mutated allele in *MPI*, named the syndrome CDG-Ib, and demonstrated the clinical and biochemical effect of mannose administration.³ Subsequently, Schollen et al identified a second pathogenic variant in *MPI* in the same patient, confirming compound

heterozygosity and autosomal recessive inheritance. Genomic organisation of the human *MPI* gene was determined: it is composed of eight exons and spans only 5 kb.⁴ The diagnosis of the first patients^{1,2} was genetically proved by Vuillaumier-Barrot et al and Kjaergaard et al, respectively.^{5,6}

4 | BIOCHEMISTRY AND PATHOGENESIS

MPI is mainly a cytosolic enzyme (but it can be also localised in the plasma membrane) which catalyses the first step of biosynthesis of nucleotide sugar mannose-GDP, that is, interconversion of fructose-6-phosphate to mannose-6-phosphate (Figure 1A). Mannose, an epimer of glucose which has five times higher non-enzymatic glycation activity than glucose,⁷ is generated by two metabolic pathways—the endogenous pathway requiring MPI and the exogenous pathway using mannose contained in small amounts in the diet (eg, in oranges, apples, peaches, locust beans).⁸⁻¹⁰ Marginally, it can be also generated from endogenous glycoconjugates, glycogen, and gluconeogenesis.^{11,12} Mannose-6-phosphate deficiency, a defect in the endogenous pathway resulting from MPI deficiency, leads to impaired protein *N*-glycosylation with laboratory abnormalities indistinguishable

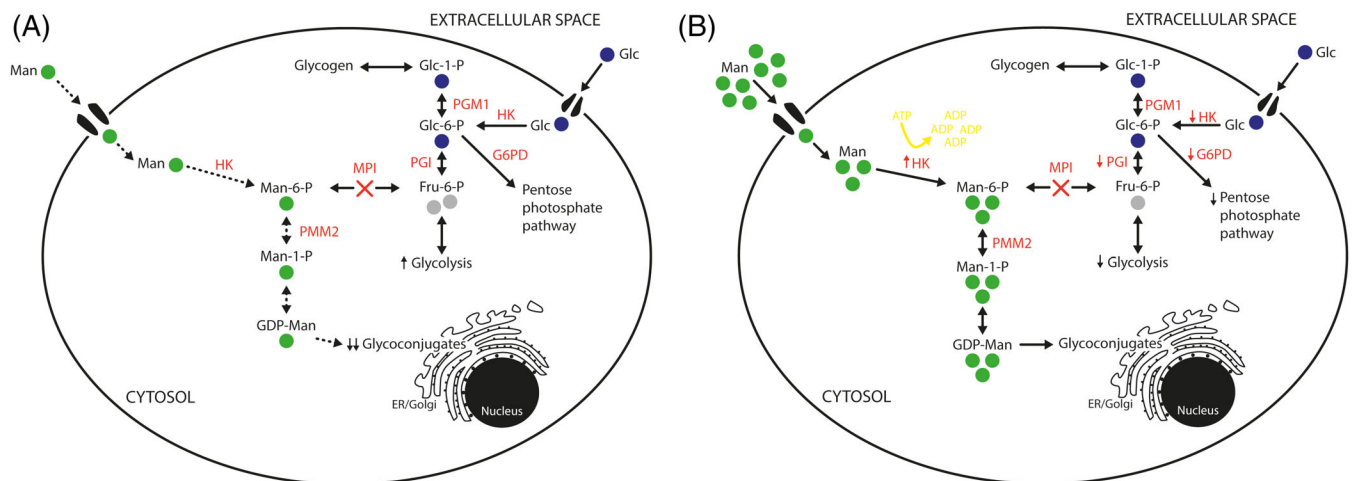


FIGURE 1 Scheme of mannose metabolism in MPI deficient cell. A, MPI deficiency causes metabolic block in endogenous pathway generating mannose. Under normal diet, the exogenous mannose is not sufficient to maintain normal intracellular mannose levels (less than 10 $\mu\text{mol/L}$ in MPI-CDG patients compared to 50-100 $\mu\text{mol/L}$ in healthy individuals) and results in protein *N*-hypoglycosylation. B, The enzymatic block can be bypassed by mannose therapy. Serum mannose level over 200 $\mu\text{mol/L}$ normalises the protein glycosylation. However, the excessive mannose substitution can cause the intracellular energy failure induced by Man-6-P accumulation. The Man-6-P inhibits the HK, PGI, and Glc-6-P dehydrogenase activity, decreases level of glycolysis, causes depletion of intracellular ATP and subsequent energy failure. ADP, adenosine diphosphate; ATP, adenosine triphosphate; ER, endoplasmic reticulum; Fru-6-P, fructose-6-phosphate; HK, hexokinase; G6PD, glucose-6-phosphate dehydrogenase; GDP-Man, Guanosine diphosphate-mannose; Glc, glucose; Glc-1-P, glucose-1-phosphate; Glc-6-P, glucose-6-phosphate; Man, mannose; Man-1-P, mannose-1-phosphate; Man-6-P, mannose-6-phosphate; MPI, mannose phosphate isomerase; PGI, phosphoglucose isomerase; PGM1, phosphoglucomutase 1; PMM2, phosphomannomutase 2

from PMM2-CDG³ because exogenous mannose is not able to compensate metabolic needs under normal dietary conditions. Mannose plasma levels in MPI-CDG patients are less than 10 $\mu\text{mol/L}$ ¹³ compared to 50 to 100 $\mu\text{mol/L}$ in healthy individuals.¹⁴ However, the enzymatic block can be therapeutically bypassed by dietary mannose supplementation which should increase serum mannose levels over 200 $\mu\text{mol/L}$.^{3,15} The exogenous mannose pathway is also a possible explanation for the absence of developmental impairment in MPI-CDG as circulating maternal mannose reduces the prenatal glycosylation defect in cerebral tissues.¹⁶

MPI-CDG by itself does not cause accumulation of toxic substrates, because fructose-6-phosphate is an intermediate of glycolytic pathway (Figure 1A). However, the excessive mannose substitution in MPI-CDG can cause the accumulation of mannose 6-phosphate (M6P) as described in the patient presenting seizures and stupor after intravenous infusion of mannose.¹⁷ The neurological symptoms seem to be caused by the intracellular energy failure induced by M6P accumulation. The M6P inhibits the hexokinase (HK), phosphoglucose isomerase (PGI), and glucose 6-phosphate dehydrogenase activity, decreases glycolysis, causes depletion of intracellular ATP and subsequent energy failure (Figure 1B). This effect was first observed in honeybees suffering from natural MPI insufficiency, and so it is known as “the honeybee effect.”^{18–20}

The mannose toxicity has been also studied in other animal models. In MPI-null mice, the prenatal mannose supplementation accelerated embryonic death by accumulation of M6P and disrupted placental architecture.²¹ In MPI-deficient mice with 14% residual enzymatic activity, both prenatal and neonatal 2% mannose supplementation led to ocular defects and blindness as the eyes have the lowest MPI activity.²² In contrast with this, the addition of mannose to the ambient water restored glycosylation and minimalised the embryonic death in zebra fish.¹⁶

Fortunately, in humans, the oral supplementation with mannose was found to normalise clinical and biochemical signs of the disease without major side effects in MPI-CDG.³ There have been no reports of embryonic lethality, however further testing should be made and until then caution in use of mannose (or mannose containing antibiotics) during pregnancy is recommended.²³

5 | METHODOLOGY

These guidelines follow the framework of international CDG expert group on PMM2-CDG guidelines.²⁴

A systematic literature review was performed on November 18, 2018 using mainly the medical database PubMed and the following key words: “MPI-CDG,” “CDG

syndrome type Ib,” “CDG-Ib,” “CDG1B,” “carbohydrate deficient glycoprotein syndrome type Ib,” “CDG type Ib,” “phosphomannose isomerase deficiency,” “congenital disorders of glycosylation” AND “phosphomannose isomerase” OR “MPI”; “congenital disorders of glycosylation” AND “failure to thrive” OR “coagulopathy” OR “PLE” OR “hypoglycaemia.” We used no language or data filters.

We found 54 articles through PubMed database search on top of which six articles were identified through references in previous review articles and the key case series. We retrieved 56 full texts—21 case reports, 11 reviews, 8 case reports with a review, and 16 research articles. Out of these, four articles had only the abstract available and two articles were found not relevant after the text assessment. From 58 relevant articles, 38 articles contained mainly information about clinical presentation and 20 articles were focussed on pathophysiology, animal models, genetics, and therapeutics. We have classified the literature evidence levels according to the methodology of Scottish Intercollegiate Guidelines Network (supplementary Table S1).²⁵ Most of the articles were of low evidence (case reports and case series), like in most rare disorders. However, the combination of the available evidence and expert opinions of the authors has enabled to establish these guidelines.

Twenty-one international experts (including 17 metabolic experts, 2 geneticists, and 2 biochemists) were assembled from 13 different centres and 9 countries. The work was distributed among several subgroups which reviewed the literature, collected the data and formed the final summaries and recommendations of the following topics: liver involvement, gastrointestinal involvement, neurological involvement, endocrine involvement, other organ involvement, coagulation abnormalities, diagnostics, and therapy. The clinical recommendations and the most appropriate frequency of examinations were based on literature review of the topic and the clinical experience with MPI-CDG and similar metabolic patients and discussion of clinical practice in different metabolic centres. The recommendations were discussed among the authors to reach consensus.

6 | RESULTS

The description of different organs' involvement and experts' recommendations are listed in the following section. The most common clinical and laboratory symptoms and their reported frequency in MPI-CDG patients are summarised in Figure 2. Summary of clinical recommendation for surveillance (Table 1) and for therapeutic management (Table 2) of MPI-CDG patients are also included.

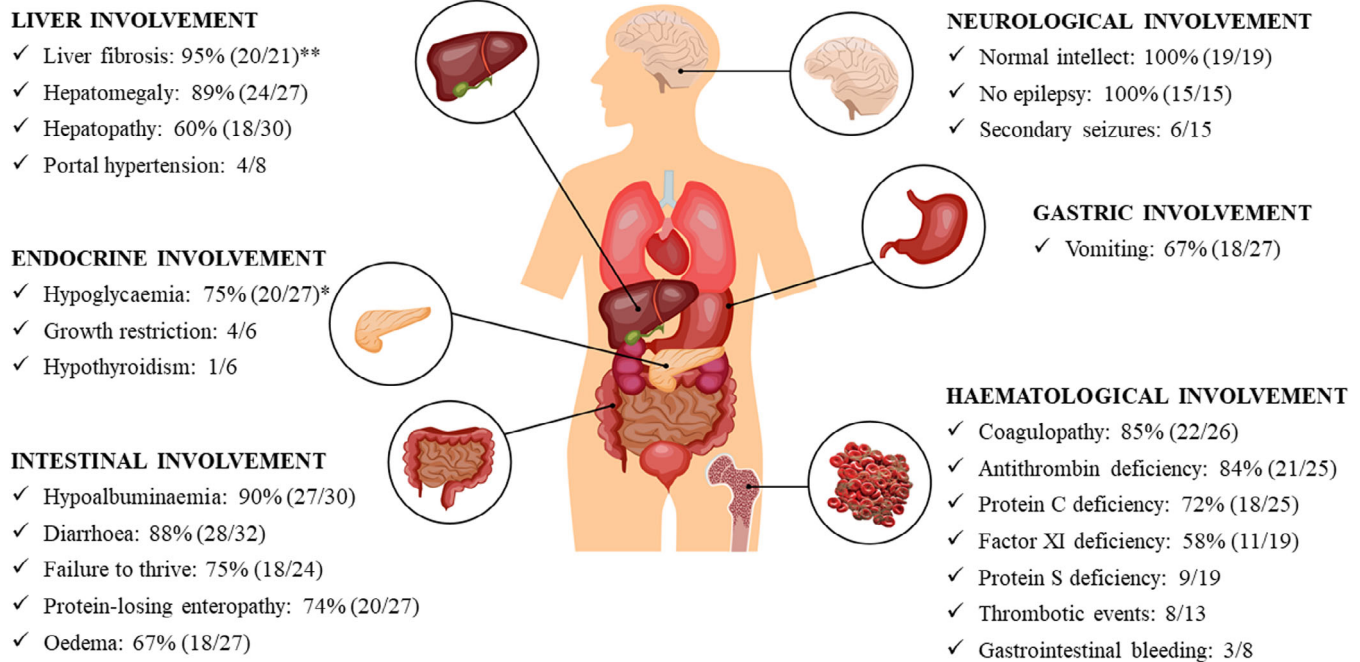


FIGURE 2 The most common clinical features and laboratory abnormalities in MPI-CDG. The classic triad of symptoms in MPI-CDG associates digestive, hepatic, and endocrine symptoms, whereas the neurologic involvement is typically absent. The figure shows the list of the most common symptoms and their frequency before mannose treatment, which was calculated as a ratio of positive cases to all published cases with sufficient clinical information. The percentage is stated, only if more than 10 patients with a respective symptom were described. * Hyperinsulinaemic hypoglycaemia was documented in 10 out of 13 investigated patients. ** Confirmed on liver biopsy. CDG, congenital disorder of glycosylation; MPI, mannose phosphate isomerase

6.1 | General demographic information

We reviewed cases of 35 patients from 30 families. The disease is panethnic, 14 patients originated from Europe (French n = 4, Swedish n = 2, Danish n = 2, German n = 1, Dutch n = 1, Spanish n = 1, Austrian n = 1, Polish n = 1, mixed n = 1), five from Northern America, four were Turkish, three were Arabic and one was Asian (not specified in eight patients). The gender ratio was 2:1 (18 females, 9 males, not mentioned in eight cases), but this disproportion was probably mainly due to the small number of patients. The age of patients ranged from 4 months to 37 years with median age 5.8 years; eight patients were adults.

6.2 | Disease onset

The onset of disease symptoms was in infancy in large majority of patients (93%) with the average age of onset being at 1.2 years, only two patients manifested in their adolescence and two adult siblings remained clinically asymptomatic to early 40s.²⁶ The presenting symptoms were mainly combination of gastrointestinal involvement

(cyclic vomiting, PLE and failure to thrive, n = 26), hypoglycaemia (n = 15), hepatic involvement (elevation of transaminases, hepatomegaly, liver fibrosis, n = 14), and coagulation complications (laboratory coagulopathy, thrombosis, intestinal bleeding, n = 7). In a group of nine patients, the disease manifested itself as isolated gastrointestinal involvement. One patient showed predominantly severe hypoglycaemia with mild hepatopathy,²⁷ we presume that isolated hypoglycaemia can exist in some patients. The diagnostic delay ranged from 0 to 30 years with median of 2.15 years; the diagnosis was made post-mortem in six patients.

6.3 | Mortality

The mortality rate was 23.5%, and all the eight patients died in their infancy and early childhood (at the age from 4 months to 5 years, median age 2.2 years). The causes, if known, were either hepatic failure (n = 2) or sepsis (n = 1); six out of eight patients died before the underlying cause and treatment of MPI-CDG was known. One patient died of the disease shortly after initiation of mannose without apparent connection with the treatment.²⁸

TABLE 1 Summary of clinical recommendation for surveillance of MPI-CDG patients

Organ involvement	At diagnosis	Every 3 mo	Every 6 mo	Every 12 mo	According to the results	Comments
<i>Liver</i>						
Liver tests (transaminases, GGT, bilirubin), alpha-fetoprotein, prothrombin time	X	(X)	X			Every 3 mo (or more often) in marked pathology
Liver ultrasound	X		X	(X)		Eventually every 12 mo depending on the severity of liver involvement. In search of nodular transformation and hypertension portal signs
Oesophageal endoscopy				X		In patients with portal hypertension—annually at the beginning of follow-up, then according to the findings at least every 3 yrs
Consultation with paediatric hepatologist			X			
<i>Gastrointestinal</i>						
Anthropometric parameters	X		X			Every follow-up visit (every 6 mo in children, once a year in adults)
Nutritional parameters (prealbumin, blood lipids, urea and creatinine, electrolyte, mineral and trace elements level, vitamins, ...)	X			X		
Faecal A1AT	X				X	Whenever hypoalbuminaemia develops
Albumin	X	X	(X)		X	More often in case of severe PLE. Every 6 mo in the absence of PLE
<i>Endocrine</i>						
Growth	X			X		
Glycaemia	X	X	(X)		X	Regular self-monitoring or continuous monitoring in severe hypoglycaemia
Insulin, C-peptide, cortisol, lactate, fatty acids, urinary ketones	X	(X)	(X)		X	In hypoglycaemic patients every 3 to 6 mo; critical sample during hypoglycaemia for the diagnosis of HH
Thyroid function, IGF1, IGFBP-3, ALS	X			X		
Calcium, magnesium, and phosphate, ALP, PTH	X			X		
Gonadotropins, oestradiol, testosterone				X		From the puberty
<i>Haematologic</i>						
Clinical signs of bleeding		X				
Complete blood count and differential	X			X		
Broad haemostatic study (prothrombin time, partial thromboplastin time, fibrinogen, f. VIII, IX, XI, AT, PC, and PS and eventually f. II, V, VII, and X)	X			X		At diagnosis and then annually
Basic haemostatic study (prothrombin time, partial					X	In case of imminent decompensation of coagulation (intercurrent infections,

TABLE 1 (Continued)

Organ involvement	According to the results				Comments
	At diagnosis	Every 3 mo	Every 6 mo	Every 12 mo	
thromboplastin time, fibrinogen, f. XI, AT, PC, and PS)					dehydration, severe PLE, before and after invasive procedures, etc.)
Doppler ultrasound and/or CT, MRI, or direct angiography				X	If thrombosis suspected
<i>Neurologic</i>					
Developmental and cognitive assessment	X			X	
Blood insulin, cortisol, GH, ammonia, lactic acid, and urinary ketones				X	In case of hypoglycaemic convulsions
Broad haemostatic study				X	In case of seizures accompanied with stroke or cerebral thrombosis
Imaging of CNS (CT angio or MRI)				X	In the new onset seizures or in case of acute deterioration of mental status
<i>Renal</i>					
Renal functions	X			X	
Renal ultrasonography	X			X	At diagnosis and then in case of pathology
<i>Cardiac</i>					
Echocardiography	X		(X)	X	In patients with portal hypertension annually, in patients without portal hypertension at diagnosis and then if new corresponding symptoms appear
Oximetry	X		X		Every follow-up visit
<i>Immunologic</i>					
Immunoglobulins	X		X		More often in case of hypogammaglobulinaemia with or without PLE
Broader immunological tests				X	In case of recurrent, severe, or opportunistic infections
<i>Mannose therapy monitoring</i>					
Unconjugated bilirubin, blood count, HbA1C, and mannose levels		X			In patients undergoing oral mannose supplementation
Neurological status, unconjugated bilirubin, blood count, and hexosuria				X	Daily, in patients undergoing IV mannose supplementation

Abbreviations: A1AT, alpha-1 antitrypsin; ALP, alkaline phosphatase; ALS, acid-labile subunit; AT, antithrombin; CDG, congenital disorder of glycosylation; computer tomography; GGT, gamma-glutamyl transferase; GH, growth hormone; HbA1C, glycated hemoglobin; HH, hyperinsulinaemic hypoglycaemia; IGF1, insulin-like growth factor 1; IGFBP-3, IGF-binding protein 3; mo, months; MPI, mannose phosphate isomerase; MRI, magnetic resonance imaging; PC, protein C; PLE, protein-losing enteropathy; PS, protein S; PTH, parathyroid hormone; yrs, years.

6.4 | Liver involvement

Liver involvement is the most frequent in the classic triad of symptoms in MPI-CDG associating digestive, hepatic, and endocrine symptoms.²⁹⁻³¹ Only two siblings have been described as detected incidentally in adulthood without liver or intestinal disease.²⁶

Hepatomegaly is the most common clinical sign, sometimes associated with splenomegaly that is not initially present in the case of early diagnosis, but that appears in the first year of life. The main complication in adulthood is the portal hypertension with oesophageal varices.^{1,32-36} Bleeding from oesophageal varices and hematemesis is less common.^{1,33,34,36} Only one patient

required liver transplant because of hepatopulmonary syndrome linked to portal hypertension, but without liver dysfunction. Liver transplantation led to overall clinical improvement, restoration of pulmonary functions and normalisation of coagulation parameters and transferrin isoelectric focusing (TIEF) pattern; however, the MPI enzymatic activity and glycosylation of non-liver derived glycoproteins remained deficient.³³

Elevation of transaminases is a common finding in MPI-CDG—transaminases are usually only slightly elevated (1.5–5 above the upper limit) but the level can reach up to 30- to 40-fold of normal values during acute decompensations.^{28,37} Nevertheless, transaminases can also be normal despite hepatomegaly and liver involvement.^{1,2,36,38} Gamma-glutamyl transferase (GGT) and bilirubin levels are often normal. Hypoglycaemia and alteration of coagulation factors are frequent findings at the time of diagnosis but represent the effect of systemic glycosylation abnormalities rather than hepatic failure. Likewise, hypoalbuminemia in majority of cases is due to exudative enteropathy and not due to hepatic failure.

Liver biopsy, when performed, can often show liver fibrosis^{1,2,28,29,35,36,39–48} or steatosis.^{42,45,48} However, the most characteristic lesion mimics those seen in congenital hepatic fibrosis, with an excess of dilated bile duct structures in ductal plate configuration in the portal tracts^{29,37,40,41,43,46} and hamartomatous formation of bile ducts, that is, von Meyenburg complexes.²⁸

Mannose supplementation improves clinical and biological parameters; however, patients can still develop progressive liver fibrosis.^{41,46} As the typical histological lesions represent congenital/developmental abnormalities of the liver (ie, ductal plate malformation), they do not respond to mannose therapy.

6.4.1 | Clinical presentation (statement #1: grade of recommendation D)

Liver involvement in MPI-CDG is one of the most common features. Patients often present with mild hepatopathy, hepatomegaly, and hepatic fibrosis. The rare but serious complications are portal hypertension with or without oesophageal varices and hepatopulmonary syndrome.

6.4.2 | Differential diagnosis (statement #2: grade of recommendation C)

The differential diagnosis of chronic liver disease is wide. It comprises various genetic and inherited metabolic diseases (aldolase B deficiency; Alpers progressive infantile poliodystrophy; alpha-1 antitrypsin [A1AT] deficiency;

classic galactosaemia; cystic fibrosis; Gaucher disease; glycogenosis type IV; glycerol-3-phosphate dehydrogenase 1 deficiency; hemochromatosis; long-chain 3-hydroxyacyl-CoA dehydrogenase deficiency; lysosomal acid lipase deficiency; Niemann-Pick disease types A, B, and C; peroxisomal disorders; S-adenosine homocysteine hydrolase deficiency; transaldolase deficiency; tyrosinemia type I; urea cycle disorders; Wilson disease) including other CDGs, especially those where the liver involvement is present as a predominant symptom (TMEM199-CDG, CCDC115-CDG, and ATP6AP1-CDG).³⁰ Excessive alcohol consumption and viral hepatitis should be also excluded. Bile duct involvement in MPI-CDG with ductal plate malformation is very similar to those observed in Congenital Hepatic Fibrosis in Autosomal Recessive Polycystic Kidney Disease.

6.4.3 | Diagnosis and follow-up (statement #3: grade of recommendation D)

To the best of our knowledge, all the patients have liver involvement even at minimal stage, so the liver tests (transaminases, GGT, bilirubin, alpha-fetoprotein, prothrombin time) and liver ultrasound (in search for liver fibrosis, steatosis, ductal plate malformations, or signs of portal hypertension) should be performed every 6 months. In patients with chronic elevation of transaminases, the development of liver fibrosis or cirrhosis can be monitored with non-invasive elastography techniques once a year. The identification of evolution to cirrhosis is important, given the occurrence of potentially life-threatening complications (variceal bleeding, hepatocellular carcinoma, ascites) associated with cirrhosis.

For patients with portal hypertension (ie, thrombocytopenia, splenomegaly or collateral circulation on abdominal ultrasound), oesophageal endoscopy should be performed each year at the beginning of the follow-up and thereafter depending on the endoscopic findings, but at least every 3 years. Oesophageal varices could be treated as in any portal hypertension situation. For patients with portal hypertension, the extrahepatic complications should be checked annually: cardiac echography (portopulmonary hypertension) and oximetry while lying down and standing with or without contrast cardiac ultrasound (hepatopulmonary syndrome). Patients without portal hypertension should undergo echocardiography in the time of diagnosis and then when new clinical symptoms suggesting hypertension appear.

As the liver involvement in MPI-CDG is irreversible and progressive, the further liver damage should be prevented by vaccination against hepatotropic viruses (hepatitis A and B), avoidance of hepatotoxic drugs, and alcohol abstinence.

TABLE 2 Summary of clinical recommendation for therapeutic management of MPI-CDG patients

Organ involvement	Therapy	Comments
Causal treatment	Oral mannose (150-170 mg/kg/dose 4 to 5 times daily)	
	IV mannose (continuous infusion up to 1 g/kg/d)	In life threatening conditions; in combination with individualised IV glucose intake
Liver	Liver transplantation	In selected cases (liver failure, portal hypertension with hepatopulmonary syndrome)
Gastrointestinal	Parenteral nutrition	In undernourished patients with chronic diarrhoea or recurrent vomiting
	Albumin infusion (20% solution)	In patients with serum albumin <2 g/dL and oedema
	i. v. or s. c. immunoglobulins oral mannose (dto)	In patients with hypogammaglobulinaemia
Endocrine (hypoglycaemia)	Frequent feedings	Addition of complex carbohydrates to the diet is needed in patients with confirmed hyperinsulinaemia
	i. v. glucose to keep blood glucose concentration >4 mmol/L	Needed in acute states like gastrointestinal tract infection, in severe acute hypoglycaemia, if a patient is not fed orally, perioperative management ^a
	Oral diazoxide 4-15 mg/kg/day divided to three or four doses oral mannose (dto)	If confirmed hyperinsulinaemia
Haematological	Oral mannose (dto)	Usually leads to the correction of coagulopathy
	However, if coagulopathy persists:	Avoid VKA in case of digestive ulceration and/or oesophageal varices
	• <i>In case of thrombosis:</i>	
	UFH LMWH VKA	
	• <i>In case of bleeding:</i>	Avoid concentrates of FXI and/or rFVIIa
	local haemostatic procedures fresh frozen plasma	
• <i>In case of surgery:</i>	Avoid concentrates of FXI and/or rFVIIa Thromboprophylaxis according to the guidelines	
	fresh frozen plasma AT concentrate	

^aDiscontinue the intravenous infusion only after the child tolerates food.

Abbreviations: AT, antithrombin; CDG, congenital disorder of glycosylation; FXI, factor XI; LMWH, low-molecular-weight heparin; MPI, mannose phosphate isomerase; rFVIIa, recombinant factor VIIa; UFH, unfractionated heparin; VKA, vitamin K antagonist.

6.4.4 | Treatment (statement #4: grade of recommendation D)

Mannose is the main treatment modality (see relevant Section 6.11); however, it is unlikely to treat or prevent the liver dysfunction. Liver transplantation has been performed in one patient and could be necessary in selected cases (such as in patients with hepatopulmonary syndrome due to portal hypertension). The role of pharmacologic therapy (eg, non-selective beta-blockers) or shunting procedures (eg, transjugular portosystemic shunt or distal splenorenal shunt) to manage portal

hypertension remains unstudied but could be of benefit when there is preserved hepatic function (as evidenced by normal prothrombin time and the absence of hepatic encephalopathy).

6.5 | Gastrointestinal involvement

Gastrointestinal symptoms are among the most common features of MPI-CDG and they are often the first clinical presentation. The onset of gastrointestinal impairment is in infancy in the majority of patients. Two patients, who

developed severe gastrointestinal symptoms in their adolescence, have been described.⁴⁹

Diarrhoea is the most common gastrointestinal symptom. It can be isolated^{1,28,29,45,50} or more commonly associated with vomiting. Only one patient presented with vomiting without diarrhoea.³⁵ The diarrhoea and vomiting are sometimes of cyclic pattern.^{28,37,40,51} Gastrointestinal episodes leading to dehydration often required recurrent hospital admissions.

The diarrhoea is most commonly due to PLE with resulting hypoalbuminaemia. The suggested mechanism of pathogenesis is loss of intestinal wall's integrity due to reduction of glycoproteins on the enterocytes' membrane³⁴ or lymphangiectasia.^{2,29,42,48} Faecal A1AT, as a diagnostic marker of PLE,⁵² was examined only in a few patients with PLE—the elevation was from 3- to 20-fold normal values.^{28,40,45} Two patients with diarrhoea had normal faecal A1AT.⁴⁰

The severity of hypoalbuminaemia can vary, it can often lead to oedema^{1-3,6,28,29,37,42,46,48} and it sometimes requires repeated intravenous albumin infusions.^{2,28,29} Hypoalbuminaemia was reported in three patients with no documented exudative enteropathy but with no other signs of impaired liver synthesis.^{27,28,40,41}

Steatorrhea was reported in three cases.^{42,48}

The gastrointestinal impairment often leads to malnutrition/failure to thrive, which were reported in two-thirds of patients, although the anthropometric measurements were available in only half of them. It was mostly associated with recurrent vomiting and diarrhoea, except of two patients: one with hypertrophic cardiomyopathy, feeding difficulties, hepatomegaly, and liver fibrosis,²⁸ and another with hypoglycaemia and hepatomegaly.³⁸ Patients with severe gastrointestinal presentation (and/or with severe hypoglycaemia) require parenteral nutrition^{2,46,49} and/or feeding via nasogastric tube^{29,35} or gastrostomy.^{29,37}

Two patients suffered from recurrent gastrointestinal ulcerations, which responded to antacids.^{35,45} One case report describes a patient with coexisting Crohn disease and MPI enteropathy: she had typical clinical (loose stools, perianal fistulas, ileal stenosis) and histological findings (marked intestinal wall thickening, active inflammation, ulcerations, and small abscesses) and was treated with diverse anti-inflammatory therapy for 13 years with insufficient effect. Introduction of mannose led to prompt alleviation.⁴⁹

Duodenal biopsies, when performed, reveal a mild villous atrophy^{2,8,29,42,43,48,50} and less frequently lymphangiectasia.^{2,29,42,48} Enterocolitis cystica was reported in the group of four first described patients.² However, duodenal biopsy can be normal, even in patients with PLE.^{37,40,49}

Mannose supplementation corrected hypoalbuminaemia in all patients with PLE^{3,8,28,32,37,43,45,46,50} and resolved diarrhoea and vomiting episodes. In patients with villous atrophy, biopsies after treatment showed normalisation of the histologic findings.^{8,50}

Experimental heparin treatment of severe PLE was described in patient with serious adverse reactions after mannose.³⁴ It is suggested that heparin binds inflammatory cytokines that would damage intestinal tight junctions resulting in protein leakage.⁵³⁻⁵⁵ The effect on gastrointestinal symptoms is convincing but the risk of bleeding in patients with coagulopathy and/or portal hypertension and/or oesophageal varices should be considered.

6.5.1 | Presentation (statement #1: grade of recommendation D)

Digestive features are frequent and often the presenting symptoms of MPI-CDG. Patients present with recurrent vomiting, diarrhoea, failure to thrive and PLE with hypoalbuminaemia.

6.5.2 | Differential diagnosis (statement#2: grade of recommendation C)

MPI-CDG should be included in the differential diagnosis of patients with a PLE. It can be caused by various gastrointestinal diseases including gastrointestinal infections (eg, cytomegalovirus, giardiasis, Whipple disease), severe celiac disease, idiopathic bowel diseases, other congenital metabolic diseases (eg, ALG6-CDG) and intestinal lymphangiectasia in different genetic disorders (eg, Noonan and Turner syndrome, FGFR3 skeletal dysplasia with PLE).

The diagnosis of MPI-CDG should also be considered in cases of chronic diarrhoea or cyclic vomiting, particularly if associated with hepatomegaly/hepatic fibrosis or coagulopathy. In the differential diagnosis of hypoalbuminaemia, liver, kidney, and eating disorders should also be considered.

6.5.3 | Diagnosis and follow-up (statement# 3: grade of recommendation D)

Monitoring of anthropometric parameters (every 6 months in children and once a year in adults) as well as nutritional status (serum prealbumin, blood lipids, urea and creatinine, electrolyte, mineral and trace elements

level, vitamins, etc.) once a year, is recommended. A PLE should be suspected in patients with oedema and hypoalbuminaemia, without proteinuria or liver synthesis impairment. The diagnosis is confirmed by an increase of A1AT in stool, using a spot determination or more formally by calculating the clearance of A1AT. Frequency of serum albumin determination depends on the presence and severity of PLE and treatment response.

6.5.4 | Treatment (statement# 4: grade of recommendation D)

At presentation, severely undernourished patients with chronic diarrhoea or recurrent vomiting may require parenteral nutrition. Mannose supplementation is associated with a regression of PLE and a resolution of vomiting and diarrhoea episodes. However, before clinical and biochemical normalisation, intravenous albumin supplementation may be necessary.

6.6 | Endocrine involvement

Endocrine involvement in MPI-CDG comprises mainly hypoglycaemia. The abnormal glycosylation of transport proteins, hormones, and regulators (eg, insulin-like growth factor binding protein 3 [IGFBP-3], acid-labile subunit [ALS], and thyroxine-binding globulin [TBG]), might also cause pubertal delay, growth restrictions and impaired thyroid gland function, although it has been described only in single cases.

Hypoglycaemia has been observed in the majority of reported MPI-CDG patients.^{2,6,8,27-29,32,35,37,38,42,43,46,49,50} The manifestation was mainly in infancy (first hypoglycaemia observed from perinatal period to 3 years of age) with mean age of presentation 6.8 months. Six patients presented symptomatic hypoglycaemia with seizures^{2,8,27,29,32,37,43} and/or irresponsiveness and apnoea.²⁹

The most common cause of hypoglycaemia in these patients was hyperinsulinism (HH), which is present in more than two-third of hypoglycaemic patients. HH has also been reported in other CDG such as PGM1-CDG⁵⁶⁻⁵⁸ and PMM2-CDG.^{32,59} However, the exact cause of HH in CDG patients is still unknown. Some of the hypotheses include hypoglycosylation of membrane receptors such as sulfonylurea receptor SUR1,⁶⁰ which is important for insulin release. It has been shown that hypoglycosylation in murine pancreatic beta cells (MIN6) can alter the insulin secretion.⁶¹ Three of the reported patients presented with hypoglycaemia without HH.^{8,37,49}

Hypoglycaemia in most patients was managed by diazoxide, glucagon, glucose, mannose, or the combination

of those. Some patients required continuous feeding for maintaining euglycaemia.³⁷ The mannose treatment had favourable effect on hypoglycaemia in both patients with HH and in patients with the unknown underlying cause of hypoglycaemia, supporting the importance of glycosylation in maintaining normoglycemia.

Thyroid dysfunction was reported only in one patient—the necessity of supplementation was not specified.²⁸ Two patients were diagnosed with TBG deficiency with normal thyroid-stimulating hormone (TSH) and free thyroxine (FT4) levels.^{28,37} Four other patients had reported normal levels of thyroid hormones.^{8,28,32,42}

Growth restriction was documented in four patients. In the first one, decreased levels of IGF1, ALS, and IGFBP-3 (with hypoglycosylation of the latter two) were documented with improvement and catch-up on mannose treatment.⁶² The other had also dominant growth restriction without failure to thrive and with normal growth hormone (GH) and insulin-like growth factor (IGF) levels.⁸ Two other patients had growth restriction with dominant failure to thrive.^{29,38}

Pubertal delay was not documented in any patient. Normal course of pregnancy was noted in two MPI-CDG women.^{26,36} Levels of other hormones (GH, Luteinizing hormone [LH], follicle-stimulating hormone [FSH], testosterone), if mentioned, were normal.^{3,27,37}

6.6.1 | Clinical manifestation (statement #1: grade of recommendation D)

Hypoglycaemia is frequently associated with MPI-CDG and, it can be a presenting and rarely even the only sign. Hypoglycaemia results mainly from HH, although the insulin level can as well be normal. The severity of hypoglycaemic episodes is heterogeneous ranging from asymptomatic hypoglycaemia to severe hypoglycaemia accompanied with seizures. The symptoms may be present at birth.

Other endocrine symptoms seen in MPI-CDG are growth restriction due to ALS and IGFBP-3 hypoglycosylation, hypothyroidism and benign TBG deficiency, but those are much less common.

6.6.2 | Differential diagnosis (statement #2: grade of recommendation C)

Persistent hypoglycaemia is a common symptom in numerous metabolic and endocrine disorders. Inborn errors of metabolism manifesting with hypoglycaemia and hepatopathy should be considered in differential diagnosis, such as aldolase B deficiency, defects in β -oxidation

of fatty acids, other CDG (PGM1-CDG, PMM2-CDG), glycogen storage diseases, or galactosaemia.

Congenital endocrine disorders such as Beckwith-Wiedemann syndrome (in cases with mild hemihypertrophy and macroglossia), congenital hypopituitarism, and congenital adrenal hyperplasia should be considered.

Even though some of those diseases (defects in β -oxidation of fatty acids and congenital adrenal hyperplasia) are part of a newborn screening in some countries, the most severely affected patients can manifest before receiving the results.

6.6.3 | Diagnosis and follow-up (statement #3: grade of recommendation D)

Transferrin IEF should be part of the examination algorithm of persistent hypoglycaemia, especially if the HH, hepatopathy, or enteropathy are present.

Close monitoring of hypoglycaemia is crucial, as it is the main presenting sign of MPI-CDG. Plasma insulin, C-peptide, blood glucose, HbA1C, cortisol, lactic acid, fatty acid levels as well as urinary ketones should be checked in patients presenting with hypoglycaemia every 3 to 6 months, depending on the patient's age. Insulin level should be evaluated in connection with C-peptide and glucose level from the same blood sample. Due to high variability of insulin level in time, the few samples should be taken in 15 minutes intervals. Regular self-monitoring of glycemia or even continuous glucose monitoring may be necessary in more severe cases.

FT4, TSH, TBG, IGF1, IGFBP-3, and ALS should be measured at the time of diagnosis and then annually. LH, FSH, estradiol, and testosterone should be assessed at the age of puberty.

6.6.4 | Treatment (statement #4: grade of recommendation D)

Oral mannose treatment in a dose from 150 to 170 mg/kg/dose four to five times a day should be recommended to all MPI-CDG patients as soon as diagnosis is made because it is able to maintain normal glucose levels in majority of the patients (for more details, please see Section 6.11). Favourable effect in case of growth restriction was also documented.

Hyperinsulinaemic hypoglycaemia can be also managed by frequent feedings and by adding complex carbohydrates to the diet. Severe acute hypoglycaemia should be treated with intravenous glucose in a dose to keep blood glucose over 4 to 6 mmol/L.^{63,64} Patients with

confirmed hyperinsulinaemia and hypoglycaemia might additionally need diazoxide treatment (reported doses vary from 4 to 15 mg/kg/day divided to three doses). The diazoxide is contraindicated in pregnancy.

During acute states like gastrointestinal tract infections, perioperative time and other situations when a patient is not fed orally, one should be covered by continuous glucose infusion to keep blood glucose concentration above 4 mmol/L. Combination of IV glucose and mannose could be necessary in some of the most severe patients, however, special attention should be given in such cases, considering the adverse events of IV mannose treatment. Too low dose of glucose may provoke neurological symptoms, due to hypoglycaemia in such cases, and should be treated with glucose infusion in high doses.¹⁷

6.7 | Haematological involvement

Coagulation abnormalities with or without related clinical manifestations (ie, thrombosis or bleeding) are also almost constant finding in MPI-CDG.

Coagulopathy with typical pattern affecting both procoagulant and anticoagulant factors is reported in almost all patients, with mainly antithrombin (AT) deficiency. Deficit in protein C (PC) and in factor XI (FXI) is also frequently observed, and protein S (PS) can also be decreased. These deficits are probably related to the glycosylation abnormalities of these glycoproteins^{31,65} but may be also exacerbated by PLE episodes and liver failure, if present. Only four patients had normal levels of coagulation factors.^{26,27,42,49} These coagulation abnormalities disturb haemostatic equilibrium which may induce haemorrhagic or thrombotic event.

Thrombotic events often complicate acute infections and dehydration episodes. These are mainly deep vein thromboses of the lower extremities.^{1,3,36,65} Thromboses of the upper extremities,¹ cerebral parenchyma,² venous sinus,³⁷ and heart atrium,³² have also been described. Two patients experienced pulmonary embolism,^{49,65} in one of which the procoagulant state was supported by IBD and a corticosteroid treatment.⁴⁹ The thrombotic tendency in CDG is caused by combination of anticoagulants' deficiency^{66,67} and increased platelet aggregation.⁶⁸ Thromboses can be multiple and recurrent.^{1,3,65}

Bleeding is less frequent but it can be life threatening. The severity varies from easy bruising⁴⁹ to extensive purpuric bruising with consumptive coagulopathy⁶⁵ and repeated life-threatening diffuse intestinal bleedings.^{3,8} One patient died of intestinal (probably variceal) bleeding with hematemesis.¹ Bleeding episodes mainly affects gastrointestinal tract and may be associated with oesophageal varices or digestive ulcers.^{8,34,36} In one patient, multiple

cerebral infarcts and thromboses were found post-mortem.² The same patient can both suffer from thrombosis and bleeding.^{3,36,37}

Disseminated intravascular coagulation can sometimes be associated with MPI-CDG.^{8,65} In these cases, factors II, VII, VIII, IX, and fibrinogen can also be reduced, and D-dimers elevated.^{8,37,65}

The coagulation abnormalities can be sometimes important clue for diagnosis. In one patient, the MPI-CDG diagnosis was revealed due to the presence of multiple thrombotic complications and coagulopathy in childhood.⁶⁵ In another one, the only disease-related anomalies were slight decrease in AT and PC levels and abnormal transferrin glycosylation pattern.²⁶

Coagulation parameters normalise within weeks upon mannose treatment initiation.^{3,8,32,38,43} No thrombotic events were reported in MPI-CDG patients treated with mannose.

6.7.1 | Clinical manifestation (statement #1: grade of recommendation D)

Mixed coagulopathy affecting both procoagulant and anticoagulant factors is typical for MPI-CDG—the most common is AT, protein C, factor XI, and protein S deficiency. Thrombotic complications can develop especially during intercurrent infection or dehydration. Diffuse gastrointestinal bleeding or bleeding from oesophageal varices is rare but potentially fatal complication.

6.7.2 | Differential diagnosis (statement #1: grade of recommendation C)

MPI-CDG should be considered in the differential diagnosis of coagulopathy caused by liver failure or disseminated intravascular coagulation without an obvious cause being found, or isolated congenital deficiency of physiological inhibitor of coagulation without identified pathogenic variant in the inhibitor gene.

6.7.3 | Diagnosis and follow-up (statement #3: grade of recommendation D)

Broad haemostatic study including fibrinogen, prothrombin time, partial thromboplastin time, factor VIII, factor IX, factor XI, AT, PC, and PS, complete blood count and differential should be performed at diagnosis and then annually. In case of prothrombin time prolongation, the factors II, V, VII, and X should be also examined.

Prothrombin time, levels of factors II, V, VII, and X are also useful in evaluating liver function and should be performed on annual basis.

In case of intercurrent infection and dehydration, haemostasis study should be conducted to uncover decompensation of coagulation. The coagulation tests should be also repeated in context of PLE and before any surgery or invasive procedure and after the procedure during the recovery time. In these cases, haemostasis study should include prothrombin time, partial thromboplastin time, fibrinogen, AT, factor XI, PC, and PS as these are the most frequently affected.

6.7.4 | Treatment (statement #4: grade of recommendation D)

The mannose treatment usually leads to the correction of coagulopathy and to the disappearance of haematological symptoms. However, if the effect is insufficient and the patient presents haematological complications additional treatment may be necessary.

In case of thrombosis, treatment by unfractionated heparin or low-molecular-weight heparin can be used. Treatment with vitamin K antagonist should be considered carefully, due to the risk of bleeding, especially in case of digestive ulcerations and/or oesophageal varices. For detailed information about antithrombotic therapy, we refer to the guidelines of the American College of Chest Physician.^{69,70}

In case of severe bleeding, the patient should be treated with local haemostatic procedures and, if the levels of coagulation factors are significantly decreased, with fresh frozen plasma. Infusion of factor XI concentrate or recombinant factor VIIa (rFVIIa) is not recommended due to the high risk of thrombotic events caused by unbalanced haemostasis.⁷¹

The management of coagulopathy during surgery must take into account the levels of clotting factors and inhibitors (especially AT and FXI), the hemorrhagic and the thrombotic risk of the procedure. Prophylactic use of fresh frozen plasma should be considered if the plasmatic levels of AT and /or FXI are low. AT concentrate could be used after the haematologist advice. Factor XI concentrate or rFVIIa infusion is not recommended due to the high risk of thrombotic complications. For post-operative thromboprophylaxis, we refer to the guidelines of the American College of Chest Physician.^{69,70}

6.8 | Neurological involvement

Neurological involvement in MPI-CDG is typically absent and if present, it is mild.

Developmental delay (DD) was reported only in four cases in infancy and was mild in all cases. In two patients, the psychomotor development normalised after 18 months of age,^{29,43,72} in one patient the mild DD persisted in 2 years of age,³⁵ and in one patient the DD was presumably secondary to severe gastrointestinal disease resulting in death at 2 years.²⁸ All the remaining patients have normal psychomotor development and intellect.

Hypotonia was documented in five patients. In two of them, the muscle tone normalised during the first year of life,^{32,37,42,48,73} in one patient hypotonia was described even at 2 years³⁵ and in one patient the hypotonia could be secondary as the child was seriously ill and died at 28 months.^{42,73} Remaining two-third of patients have normal muscle tone.

Seizures were documented in six patients, but they were secondary in all cases and no chronical antiepileptic treatment was necessary. Three patients had hypoglycaemic seizures in early infancy with the median age of 3 months.^{29,32,37,42,48,72,73} Generalised convulsions with acute deterioration of mental status were described as a possible adverse effect of mannose therapy with complete restitution after glucose bolus.^{3,17} In two patients, the seizures were secondary to cerebral thrombosis (sagittal sinus thrombosis during dehydration; multiple cerebral infarcts; and thrombosis with hemiplegia), both episodes happened in late infancy; the restitution was complete in the first case and not specified in the other.^{2,37} One patient had uncomplicated febrile convulsions in early childhood.⁶⁵

Imaging of central nervous system was performed in 10 patients with physiological findings^{3,17,32,35,37,38,42,43,48,65,73}; no cerebellar hypoplasia was noted, as it is typical in other CDG.⁷⁴ Strabismus was reported in one patient at the age of 2 years.³⁵ No other neurologic abnormalities are documented in MPI-CDG patients.

6.8.1 | Clinical manifestation (statement #1: grade of recommendation D)

Neurological involvement in MPI-CDG is not a common feature. Patients can present mild DD, hypotonia, and secondary seizures. Neurologic symptoms often disappear in early childhood.

6.8.2 | Differential diagnosis (statement #2: grade of recommendation C)

Secondary seizures due to hypoglycaemia are present in congenital HH syndromes, hypocortisolism, GH deficiency, and in other CDGs and glycogen storage diseases. Convulsions might be associated with other causes of

cerebral venous sinus thrombosis or stroke in children such as congenital coagulopathy syndromes, mitochondrial diseases and disorders of phospholipid synthesis.

6.8.3 | Diagnosis and follow-up (statement# 3: grade of recommendation D)

Blood insulin, cortisol, GH, ammonia, lactic acid as well as urinary ketones should be investigated in patients presenting hypoglycaemic convulsions. A complete haemostasis study should be performed in children presenting seizures accompanied with stroke or cerebral thrombosis. Close monitoring in patients receiving IV mannose therapy is recommended as neurological side effects might occur. The CNS imaging should be considered in the new onset seizures and/or deterioration of mental status according to the standard neurologic recommendations.

6.8.4 | Treatment (statement # 4: grade of recommendation D)

Chronical antiepileptic treatment is usually not necessary in MPI-CDG patients. Symptomatic treatment of secondary seizures is recommended according to the underlying aetiology.

6.9 | Other organ involvement

6.9.1 | Antenatal involvement and dysmorphism

Antenatal involvement was not reported in any MPI-CDG case. One pregnancy was monitored for pregnancy toxicosis and expected low birth weight.³⁵ Very mild non-specific facial dysmorphism was noticed in two patients and strabismus in the second one only.^{32,35} Only one patient presented inverted nipples³⁷ and no patient presented with abnormal fat distribution nor skeletal deformity typical for other CDGs.

6.9.2 | Renal involvement

Renal abnormalities were noticed in six patients—they presented renal hyperechogenicity,^{29,42} nephromegaly,^{32,45} and cysts.⁴² One patient had non-functional kidney due to multicystic disease.² One patient was treated with oral bicarbonate for mild tubular acidosis.³⁹

6.9.3 | Cardiac involvement

The only serious cardiac involvement documented in previously published cases was non-specified hypertrophic cardiomyopathy with atrial septal defect in patient with serious phenotype; the child died of cardiac failure at 2 years of age.²⁸ One patient had atrial septal defect type II most probably unrelated to the MPI-CDG.³⁵

Cardiac dysfunction or cardiomyopathy might develop secondary to portal hypertension although it has not been documented in MPI-CDG yet. This issue and principles of patients monitoring has been described in Section 6.4.3.

6.9.4 | Immunological involvement

Immunological involvement in MPI-CDG has not been described in detail yet. However, it is known in other CDGs and MPI-CDG cases with recurrent and atypical infections have been published. One patient suffered from high frequency of unusual and severe specific infections (HSV encephalitis, bronchiolitis obliterans, cryptosporidial diarrhoea, candidal urinary tract infection) and a high frequency of respiratory infections. Although an immunodeficiency was very likely, the conventional immune function studies were normal.⁴⁵ Another four patients presented frequent episodes of fever, leucocytosis, and sepsis, although their immunological tests were within normal limits.² Immunoglobulin deficiency due to PLE (characteristic by decreased levels of IgG but normal levels of IgA and IgM) was described in six patients.^{2,28,42}

6.9.5 | Clinical presentation (statement #1: grade of recommendation D)

In contrast with PMM2-CDG, facial dysmorphism, atypical fat pads, inverted nipples, and skeletal deformities are not present in MPI-CDG patients.

Mild tubular acidosis, nephromegaly, renal cysts, and severe hypertrophic cardiomyopathy were described in sporadic cases; the connection with MPI-CDG is unclear.

Immunological involvement is common in CDGs; higher incidence of unusual infections and hypogammaglobulinaemia due to PLE can be present in MPI-CDG patients.

6.9.6 | Differential diagnosis (statement #2: grade of recommendation C)

Screening for other disorders of tubular function (eg, renal tubular acidoses, Bartter syndrome, Gitelman syndrome)

and genetic syndromes with renal cysts formation (eg, multicystic dysplastic kidney, polycystic kidney disease) should be considered. In cases of hypertrophic cardiomyopathy, a broad metabolic screening and genetic tests are necessary to rule out other diagnoses. Immunodeficiency syndromes including various CDGs should be evaluated if severe infectious complications are present.

6.9.7 | Diagnosis and follow-up (statement# 3: grade of recommendation D)

Basic biochemical parameters including renal parameters and immunoglobulin levels should be performed regularly, at least once a year. Renal ultrasonography, echocardiography and wider immunological testing can be included in the first evaluation of patient or in case of corresponding symptomatology.

6.9.8 | Treatment (statement# 4: grade of recommendation D)

Treatment of those symptoms should follow standard recommendations with no specifics for MPI-CDG. IV or SC immunoglobulins should be administered regularly in patients with hypogammaglobulinaemia. Information about the effect of mannose treatment on renal, cardiologic and immunologic involvement is not available.

6.10 | Diagnostic tools

6.10.1 | Isoelectric focusing of transferrin

Isoelectric focusing of serum/plasma transferrin (TIEF) is the preferred technique for the sensitive routine screening of MPI-CDG.^{40,75} Since the enzymatic defect alters the synthesis of GDP-mannose before the linkage of the oligomannosidic *N*-glycan chains to the nascent proteins, MPI-CDG can be biochemically characterised by a decreased level of the major tetrasialylated transferrin (Trf) glycoform (tetrasialotransferrin) and an increase of disialotransferrin and asialotransferrin, that is, CDG type I pattern. This pattern is 100% sensitive but non-specific (eg, indistinguishable from PMM2-CDG) and it has been reported in all MPI-CDG patients except those diagnosed post-mortem on basis of symptoms and/or *MPI* gene analysis in parents or siblings.^{1,2}

For TIEF analysis, serum or plasma samples should be used. Plasma samples should be collected from EDTA- or

heparin-blood by centrifugation and stored at -20°C . Extra care should be taken when isolating serum/plasma after centrifugation since contamination by neuraminidase producing microorganisms has been shown to generate desialylation and abnormal Trf profiles.⁷⁶ Frozen samples should be thawed at 4°C and centrifuged before analysis.

Relatively frequent protein polymorphisms can complicate the interpretation of TIEF profiles by impacting its charge and generating additional protein isoforms that could mimic increase of trisialotransferrin or disialotransferrin glycoforms leading to potential false positive results.⁷⁷ In case of positive CDG screening, such polymorphisms could be unmasked by pre-incubation of the sample with neuraminidase as described in few MPI-CDG patients.⁴³ Analysis of parental transferrin can also rule out the presence of hereditary variants.

Interestingly, mannose treatment was shown to improve abnormal TIEF profiles, but complete normalisation was usually not reached.^{1,46} Complete normalisation was reported in an asymptomatic patient but the TIEF returned to pre-supplementation state after discontinuation of the therapy.⁴⁹

Characteristic of method (statement #1: grade of recommendation C)

The TIEF is preferred method for analysis of glycosylation profile of plasma/serum transferrin which is a fast and sensitive but non-specific biomarker for MPI-CDG. In MPI-CDG patients, it typically shows CDG type I pattern, that is, a decrease of the tetrasialotransferrin and an increase of disialotransferrin and asialotransferrin.

Methodology and preanalytical requirements (statement# 2: grade of recommendation D)

Serum or plasma samples should be used for MPI-CDG screening. Plasma samples should be collected from EDTA or heparin-treated blood after centrifugation and stored at -20°C . Contamination by external neuraminidase producing microorganisms should be avoided. For abnormal profile, repeating the test on an independent sample and in an experienced laboratory is recommended.

Sensitivity of method (statement #3: grade of recommendation C)

When the genotype is present, the analytical sensitivity of the TIEF pattern is 100%.⁷⁸

Specificity and differential diagnosis (statement #4: grade of recommendation C)

Other types of CDG and secondary glycosylation defects can also lead to abnormal Trf patterns. Notably, untreated galactosaemia and hereditary fructose

intolerance (fructosaemia), chronic alcohol abuse, liver disease, and severe infections can mimic CDG and should be ruled out.

Transferrin protein variants can complicate charge-based MPI-CDG screening. This can be avoided by pre-incubation of the positive samples with neuraminidase and/or by analysing parental samples if available.

In case of an abnormal profile, we recommend repeating the test on an independent sample and in an experienced lab.

Effect of treatment: (statement# 5: grade of recommendation D)

Abnormal TIEF profiles classically improve but rarely normalise under mannose treatment.

6.10.2 | Methods for quantification of hypoglycosylated transferrin

High performance liquid chromatography (HPLC) and capillary electrophoresis (CE) can also be used for the charge-based separation and accurate quantification of hypoglycosylated Trf isoforms.⁷⁹⁻⁸² When quantified, the part of the disialotransferrin (and asialotransferrin, if present) corresponds to the so-called carbohydrate deficient transferrin percentage (CDT%). This percentage is originally used for the detection of excessive chronic ethanol consumption; CDT% ranges 0.5% to 1.7% in non-drinkers, and $>1.7\%$ in excessive drinkers.⁸³ A case of asymptomatic MPI-CDG patient wrongly interpreted as alcohol abuser based on elevated CDT% values has been reported.²⁶ The CDT levels are less elevated (ie, 7%-20%) in oligo-/asymptomatic adult patients,^{26,49} compared to 38% to 50% in more severe cases.^{32,39,40}

The use of HPLC or CE methods can be advantageous as they allow simple processing of samples, the possibility of performing long series of analysis and the possibility of quantification.

Characteristic of method (statement #1: grade of recommendation C)

Charge-based separation and quantification of hypoglycosylated Trf is possible by methods of HPLC and CE. The CDT% in MPI-CDG patients rises above 6% but often up to 40% to 50% of asialo-/and disialotransferrins.

Methodology and preanalytical requirements (statement# 2: grade of recommendation D)

Serum or plasma samples should be used for MPI-CDG screening using HPLC or CE methods. For CE analysis, compatibility of plasma-EDTA should be carefully checked. Plasma samples should be collected from EDTA

or heparin-treated blood after centrifugation and stored at -20°C . Contamination by external neuraminidase producing microorganisms should be avoided. For abnormal profile, repeating the test on an independent sample and in an experienced laboratory is recommended.

Sensitivity of method (statement #3: grade of recommendation C)

When the genotype is present, the analytical sensitivity of the HPLC and CE patterns (CDT% measurement) is 100% in described patients.

Specificity and differential diagnosis (statement #4: grade of recommendation D)

Using HPLC and CE techniques, the differential diagnosis of abnormal Trf glycosylation patterns is the same as for TIEF abnormalities. Interferences related to transferin protein variants can be avoided by pre-incubation of the positive samples with neuraminidase and/or by analysing parental samples if available.

6.10.3 | Other biochemical methods

Furthermore, given that the lack of one or two *N*-glycan chains is also associated to molecular weight differences, classical Western blotting after SDS-PAGE has also been successfully applied to various serum/plasma glycoproteins for the screening of MPI-CDG.⁸⁴

Although applied to a very few of MPI-CDG cases,^{40,85} mass spectrometry (ESI-MS, LC-MS-MS, MALDI-TOF MS) of immunocaptured Trf is now emerging as a sensitive and fast laboratory tool for CDG type I screening.⁸⁶

Finally, some additional non-specific biomarkers have been scarcely described in MPI-CDG, for example, aspartylglucosaminidase activity, intercellular adhesion molecule 1, IGF system, and the (NeuAc-Gal-GlcNAc-GlcNAc) *N*-tetrasaccharide.^{62,87-90}

6.10.4 | Confirmatory testing enzyme assay

Since MPI deficiency cannot be discriminated from PMM2 deficiency and other CDGs type I by TIEF and other biochemical techniques, another confirmatory method (direct enzyme assay and/or *MPI* gene analysis) is strongly recommended for the correct diagnosis. The *MPI* enzyme assays have been carried out in the great majority of MPI-CDG patients described to date.

With very few exceptions,⁹¹ enzymatic assays were mainly performed on freshly isolated fibroblasts and/or

leukocytes as described by van Schaftingen and Jaeken⁹² with some derived techniques. Leukocytes should ideally be collected into EDTA tube and should arrive to the laboratory in less than 24 hours. The cells are lysed by sonication and *MPI* enzyme is spectrophotometrically assayed at 37°C following the reduction of NADP to NADPH in the presence of the appropriate substrate. Results are expressed in nmol/h/mg protein or in mU/mg protein and compared to established normal values.

In described MPI-CDG patients, enzyme activities were usually very deficient with activities less than 10% of normal values in both leukocytes and fibroblasts.^{3,6,32,35,37,46} Relatively high residual activities have been reported even in more severely affected patients (activities 14%-21% in leukocytes).⁴⁰ Enzymatic testing of the parents could be performed, usually showing intermediate values (30%-83%, median 50% of normal values).^{3,6,32,36,37,40} Confirmatory enzymatic *MPI* measurements should be performed by specialised laboratories under highly standardised conditions (substrate, buffers, temperature, units, etc.).

Characteristic of method (statement #1: grade of recommendation) C

MPI-CDG could be confirmed by measurement of *MPI* enzymatic activity in fibroblasts and/or leukocytes. Enzymatic testing of the parents could be performed, usually showing intermediate values.

Methodology and preanalytical requirements (statement# 2: grade of recommendation C)

Freshly isolated fibroblasts or leucocytes from EDTA blood samples (<24 hours at ambient temperature) should be used for *MPI* enzymatic measurement.

Sensitivity of method (statement #3: grade of recommendation B-C)

When realised, *MPI* enzymatic levels were systematically deficient in confirmed MPI-CDG patients.

Specificity and differential diagnosis (statement #4: grade of recommendation B-C)

If the preanalytical requirements are strictly respected, the specificity of the second-line *MPI* confirmatory enzymatic measurement is 100% in described patients.

6.10.5 | Confirmatory testing gene analysis

Diagnosis of MPI-CDG should be confirmed by *MPI* gene analysis. The *MPI* is composed of eight exons and its extent is only 5 kb. Its genomic structure is conserved

from mouse to human.⁴ The central catalytic MPI domain is highly conserved, while the rest of the MPI domains show rather low conservation status.⁹³ The human MPI and *Candida albicans* share 42% sequence homology and are therefore assumed to present a similar protein fold.⁹⁴

MPI-CDG has autosomal recessive inheritance, but surprisingly high percentage of homozygotes was present (13 out of 28 patients with known genotype). This is often caused by consanguinity in the family, which was reported in nine patients.^{2,26,27,40,65} However, two patients were homozygous without consanguinity of parents.^{6,43} The information about consanguinity is not available for one patient.^{4,35}

Among 28 published patients with known genotype, 20 different pathogenic variants were described (summarised in Table 3) with 17 missense variants, 2 frameshift-causing variants, and 1 splicing defect. No pathogenic variant or signs of instability could be identified in one allele in one patient.^{4,35} One more pathogenic variant was published with no information about the patient.⁹⁴ The most common variants are c.656G > A (p.Arg219Gln), c.457G > A (p.Arg152Gln), and c.884G > A

(p.Arg295His), which all together form about one half of all alleles. The most common missense variant p.Arg219Gln causing replacement of arginine by glutamine was also the first pathogenic variant identified in a MPI-CDG patient.³ It was described in six compound heterozygotes and interestingly also in two asymptomatic homozygous adults.²⁶

Asymptomatic CDG cases have been also described in PMM2-CDG⁹⁵ which could mean the existence of incomplete penetrance and undiagnosed CDG cases. Asymptomatic cases could be caused either by the presence of a mild variants in homozygous state (eg, p.Arg219Gln) or by the existence of modifier genes which are unknown to date. The phenotype does not seem to be predicted neither by the enzymatic activity, nor by the CDT values as the asymptomatic patients with markedly reduced enzymatic activity and highly elevated CDT values have been published.²⁶

One MPI-CDG patient has been diagnosed by whole exome sequencing on a hyperinsulinaemic hypoglycaemia infant.²⁷

The identification of disease-causing variants enables accurate prenatal diagnosis, determination of carrier

TABLE 3 Pathogenic variants and their frequency in the *MPI* gene (NM_002435.2)

Codon change	Amino acid change	Number of alleles	Prevalence of the allele (%)	Reference (first publication)
c.656G > A	p.Arg219Gln	12	21.4	3
c.457G > A	p.Arg152Gln	9	16.1	4
c.884G > A	p.Arg295His	8	14.3	6
c.1193 T > C	p.Ile398Thr	3	5.4	32
c.304C > T	p.Ser102Leu	3	5.4	29
c.413 T > C	p.Met138Thr	3	5.4	29
c.152 T > C	p.Met51Thr	2	3.6	4
c.391G > A	p.Asp131Asn	2	3.6	4
c.419 T > C	p.Ile140Thr	2	3.6	36
c.863C > T	p.Ala288Val	2	3.6	27
c.41A > C	p.Gln14Pro	1	1.8	33
c.166_167insC	p.Arg56fs	1	1.8	4
c.386A > G	p.Tyr129Cys	1	1.8	82
c.466G > A	p.Glu156Lys	1	1.8	6
c.488-1G > C	Aberrant splicing	1	1.8	4
c.748G > A	p.Gly250Ser	1	1.8	4
c.764A > G	p.Tyr255Cys	1	1.8	32
c.842_844del	p.Gly281del	1	1.8	6
c.1252G > A	p.Arg418His	1	1.8	37
c.1252C > T	p.Arg418Cys	1	1.8	94

Note: Nucleotide numbering reflects cDNA numbering with +1 corresponding to the A of the ATG translation initiation codon in the reference sequence.

status of family members, and genetic counselling. Support from a psychologist is also important for the families especially in the time of diagnosis.

Characteristic of method (statement #1: grade of recommendation C)

The diagnosis of MPI-CDG should be also confirmed by *MPI* gene analysis in patient and parents.

Methodology and preanalytical requirements (statement# 2: grade of recommendation D)

Leukocytes DNA are extracted from EDTA blood samples which must be accompanied by informed consent for genetic testing and clinical information.

Sensitivity of method (statement #3: grade of recommendation B-C)

Molecular diagnosis is performed by Sanger or Next-Generation Sequencing: genes panel or whole exome/genome. When the enzymatic defect is present, pathogenic variants were found in all described patients except for one allele in one patient.^{4,35}

Specificity and differential diagnosis (statement #4: grade of recommendation C)

Genetic testing allows to do differential diagnosis between positive CDT screening due to long-term excessive alcohol consumption or found in asymptomatic or undiagnosed patients with MPI-CDG, galactosaemia, or fructosaemia (aldolase B deficiency).

6.11 | Mannose therapy

The enzymatic defect in MPI-CDG can be bypassed by oral mannose supplementation as was proposed and proved with significant clinical and biochemical improvement more than 20 years ago.³ This treatment has been approved in the United States and Europe as a treatment for MPI-CDG⁹⁶ and multiple successful mannose therapy trials in at least 26 patients have been published.^{5,8,17,32-34,36-39,43,45,46,50,62,65,97}

Oral mannose is well absorbed in the gut, the peak blood mannose concentration is achieved 1 to 2 hours after ingestion and the half-time of mannose in the organism is 4 hours.¹³ The recommended dose ranges between 150 and 170 mg/kg/dose four to five times a day. The timing of mannose supplementation to achieve optimal efficacy is not known.^{13,36}

IV mannose could be considered in a life-threatening situation in a patient with a new diagnosis when oral intake is not possible, but extreme caution is advised due

to the potential side effects. Due to short half-life of mannose, the continuous IV mannose is preferred in a dose up to 1 g/kg/day. The combination with an individualised IV glucose intake based on blood glucose levels is necessary to prevent hypoglycaemia. Adequate venous access needs to be ensured.

Mannose treatment improves the patient's general condition and digestive symptoms, normalises hypoglycaemia and decreases the thrombosis risk, but it is not effective for liver involvement.^{13,23} On the laboratory level, mannose normalises the coagulation factors, significantly improves transferrin glycosylation pattern, and IGFBP-3 level.^{62,65} The clinical response is usually observed within a week of treatment, but the biochemical abnormalities take months to stabilise.¹³

The main side effects of mannose were abdominal pain and diarrhoea, which were documented in 40% of patients and improved either spontaneously or with a dose adjustment.^{3,28,36,37,45} Intravenous mannose treatment resulted in severe haemolysis in one patient and severe neurological symptoms in another.^{17,28} Mannose is reported to be toxic to the honeybee's kidney¹⁸ but there were no reports of kidney toxicity in the 26 patients treated. High mannose level has been correlated with elevated HbA1C and diabetes in humans.²³

In MPI-CDG patients under mannose treatment, there is a need for an efficient mannose measurement for adjusting dosage, avoiding or reducing side effects and evaluating the compliance. The commonly used monitoring method is the mannose measurement by spectrophotometry⁹⁸ at T0, T1h and T2h after mannose uptake. Mannose concentration should be over 20 µmol/L before mannose (T0) and over 100 µmol/L 1 hour thereafter (T1h). Those values should be adapted by each laboratory. In addition, one publication suggested that HbA1C monitoring could be helpful in preventing mannose over dosage in relation to the higher affinity of haemoglobin for mannose compared to glucose.⁸

Many questions need to be solved regarding mannose therapy in MPI-CDG; the duration of mannose supplementation, its teratogenicity, the safety of IV mannose, the optimum surveillance of therapy response and the use of prolonged mannose forms which could improve both the compliance and the quality of life of patients.

6.11.1 | Characteristic (statement #1: grade of recommendation D)

Oral mannose is recommended treatment for digestive symptoms, coagulopathy and hypoglycaemia, although it does not treat the liver symptoms in MPI-CDG.

6.11.2 | Posology and method of administration (statement #2: grade of recommendation D)

The recommended mannose dose ranges from 150 to 170 mg/kg/dose four to five times daily. IV mannose is not recommended for stable MPI-CDG patients due to the lack of evidence about patient's safety. The only exception for IV mannose is MPI-CDG patients with life-threatening conditions but extreme caution should be taken in these cases.

6.11.3 | Monitoring of treatment (statement #3: grade of recommendation D)

In patients undergoing oral mannose supplementation, unconjugated bilirubin, blood count, HbA1C and mannose levels should be monitored every 3 months for the optimisation of doses. In patients undergoing IV mannose supplementation, neurological status, bilirubin, blood count, and hexosuria should be monitored daily or every other day, to avoid toxicity and side effects.

Serum mannose measurement is of high interest for dietary therapy monitoring of MPI-CDG patients. Recommended mannose concentrations at T0 (before ingestion) and 1 hour thereafter (T1h) is >20 and >100 $\mu\text{mol/L}$, respectively. The testing should be performed by specialised laboratories under standardised conditions.

6.11.4 | Undesirable effects (statement #4: grade of recommendation D)

The main side effects of mannose therapy are abdominal pain and diarrhoea. Both usually respond to dose adjustment.

ACKNOWLEDGMENTS

Several authors of this publication are members of the European Reference Network for Hereditary Metabolic Diseases (MetabERN) Project ID No 739543. A. Č. and T. H. were supported by the Ministry of Health of the Czech Republic (MZ CR AZV 16-31932A), by General University Hospital in Prague, Czech Republic (RVO-VFN 64165), by UNCE 204064, and Progress Q26/LF1 Programs of the Charles University. EUROGLYCAN-omics was supported by Ministry of Education Youth and Sports of Czech Republic No. 8F19002, under the frame of E-Rare-3, the ERA-Net for Research on Rare Diseases. A. B. was supported by the European Union's Horizon 2020 Research and Innovation Program under the ERA-NET

co-fund action No 643578. E. M. was supported by National Institutes of Health (1 U54 NS115198-01 PI). P. W. was supported by the Clinical Research Foundation of University Hospitals Leuven, Leuven, Belgium.

CONFLICT OF INTEREST

The authors declare no potential conflict of interest.

AUTHOR CONTRIBUTIONS

Anna Čechová did the systematic literature review of the topic, drafted the manuscript including the tables and figures, prepared the chapter about neurological and other organs' involvement including the literature review, unified the text, finalised the manuscript, and coordinated the guidelines progress. Tomáš Honzík supervised all the steps of the article preparation, drafted the manuscript, prepared the chapter about neurological and other organs' involvement including the literature review and edited the manuscript. Pascale de Lonlay and Peter Witters supervised the manuscript preparation, prepared the chapter about liver involvement including the literature review and edited the manuscript. Muriel Girard prepared the chapter about liver involvement including the literature review and provided the list of articles focusing the liver involvement. Joana Correia prepared the chapter about gastrointestinal involvement including the literature review. Silvia Radenkovic prepared the chapter about endocrine involvement including the literature review and edited the mannose therapy part. Klaus Mohnike, Łukasz Pawliński, and Beata Kiec-Wilk prepared the chapter about endocrine involvement including the literature review. Eva Morava reviewed the literature concerning endocrine involvement and edited the manuscript. Maria Luz Couce and Luis Aldamiz-Echevarria reviewed the literature concerning endocrine involvement. Tiffany Pascreau, Delphine Borgel, and Annie Harroche prepared the chapter about coagulation involvement including the literature review. Arnaud Bruneel and Sandrine Vuillaumier-Barrot prepared the chapter about diagnostics including the literature review—Arnaud Bruneel prepared the biochemical methods and monitoring of mannose therapy; Sandrine Vuillaumier-Barrot prepared the genetic diagnostics methods and edited the table of pathogenic variants. Dulce Quelhas reviewed the literature concerning diagnostics methods. Ruqaiyah Altassan prepared the chapter about mannose therapy including the literature review. Esmeralda G. Martins reviewed the literature concerning the quality of life of patients.

ORCID

Anna Čechová  <https://orcid.org/0000-0002-5802-6006>

REFERENCES

- Pedersen PS, Tygstrup I. Congenital hepatic fibrosis combined with protein-losing enteropathy and recurrent thrombosis. *Acta Paediatr Scand*. 1980;69(4):571-574.
- Pelletier VA, Galeano N, Brochu P, Morin CL, Weber AM, Roy CC. Secretory diarrhea with protein-losing enteropathy, enterocolitis cystica superficialis, intestinal lymphangiectasia, and congenital hepatic fibrosis: a new syndrome. *J Pediatr*. 1986;108(1):61-65.
- Niehues R, Hasilik M, Alton G, et al. Carbohydrate-deficient glycoprotein syndrome type Ib. Phosphomannose isomerase deficiency and mannose therapy. *J Clin Invest*. 1998;101(7):1414-1420.
- Schollen E, Dorland L, de Koning TJ, et al. Genomic organization of the human phosphomannose isomerase (MPI) gene and mutation analysis in patients with congenital disorders of glycosylation type Ib (CDG-Ib). *Hum Mutat*. 2000;16(3):247-252.
- Kjaergaard S, Westphal V, Davis J, Peterson S, Freeze H, Skovby F. Variable outcome and the effect of mannose in congenital disorder of glycosylation type Ib (CDG-Ib). *J Inherit Metab Dis*. 2000;23:77-85.
- Vuillaumier-Barrot S. Diagnostic moléculaire des anomalies congénitales de la glycosylation. *Ann Biol Clin (Paris)*. 2005; 63 (2):135-143.
- Bunn HF, Higgins PJ. Reaction of monosaccharides with proteins: possible evolutionary significance. *Science*. 1981;213 (4504):222-224.
- Harms HK, Zimmer KP, Kurnik K, Bertele-Harms RM, Weidinger S, Reiter K. Oral mannose therapy persistently corrects the severe clinical symptoms and biochemical abnormalities of phosphomannose isomerase deficiency. *Acta Paediatr*. 2002;91(10):1065-1072.
- Herman RH. Mannose metabolism. *I Am J Clin Nutr*. 1971;24 (4):488-498.
- Panneerselvam K, Freeze HH. Mannose enters mammalian cells using a specific transporter that is insensitive to glucose. *J Biol Chem*. 1996;271(16):9417-9421.
- Fujita N, Tamura A, Higashidani A, Tonzuka T, Freeze HH, Nishikawa A. The relative contribution of mannose salvage pathways to glycosylation in PMI-deficient mouse embryonic fibroblast cells. *FEBS J*. 2008;275(4):788-798.
- Ichikawa M, Scott DA, Losfeld ME, Freeze HH. The metabolic origins of mannose in glycoproteins. *J Biol Chem*. 2014;289(10): 6751-6761.
- de Lonlay P, Seta N. The clinical spectrum of phosphomannose isomerase deficiency, with an evaluation of mannose treatment for CDG-Ib. *Biochim Biophys Acta*. 2009;1792(9):841-843.
- Alton G, Hasilik M, Niehues R, et al. Direct utilization of mannose for mammalian glycoprotein biosynthesis. *Glycobiology*. 1998;8(3):285-295.
- Rush JS, Panneerselvam K, Waechter CJ, Freeze HH. Mannose supplementation corrects GDP-mannose deficiency in cultured fibroblasts from some patients with congenital disorders of glycosylation (CDG). *Glycobiology*. 2000;10(8):829-835.
- Chu J, Mir A, Gao N, et al. A zebrafish model of congenital disorders of glycosylation with phosphomannose isomerase deficiency reveals an early opportunity for corrective mannose supplementation. *Dis Model Mech*. 2013;6(1):95-105.
- Schroeder AS, Kappler M, Bonfert M, Borggraeve I, Schoen C, Reiter K. Seizures and stupor during intravenous mannose therapy in a patient with CDG syndrome type 1b (MPI-CDG). *J Inherit Metab Dis*. 2010;33(suppl 3):S497-S502.
- de la Fuente M, Penas PF, Sols A. Mechanism of mannose toxicity. *Biochem Biophys Res Commun*. 1986;140(1):51-55.
- Freinkel N, Lewis NJ, Akazawa S, Roth SI, Gorman L. The honeybee syndrome—implications of the teratogenicity of mannose in rat-embryo culture. *N Engl J Med*. 1984;310(4): 223-230.
- Sols A, Cadenas E, Alvarado F. Enzymatic basis of mannose toxicity in honey bees. *Science*. 1960;131(3396):297-298.
- DeRossi C, Bode L, Eklund EA, et al. Ablation of mouse phosphomannose isomerase (Mpi) causes mannose 6-phosphate accumulation, toxicity, and embryonic lethality. *J Biol Chem*. 2006;281(9):5916-5927.
- Sharma V, Nayak J, DeRossi C, et al. Mannose supplements induce embryonic lethality and blindness in phosphomannose isomerase hypomorphic mice. *FASEB J*. 2014a;28(4):1854-1869.
- Sharma V, Ichikawa M, Freeze HH. Mannose metabolism: more than meets the eye. *Biochem Biophys Res Commun*. 2014b;453(2):220-228.
- Altassan R, Peanne R, Jaeken J, et al. International clinical guidelines for the management of phosphomannomutase 2-congenital disorders of glycosylation: diagnosis, treatment and follow up. *J Inherit Metab Dis*. 2019;42(1):5-28.
- Scottish Intercollegiate Guidelines Network. *SIGN 50: A Guideline Developer's Handbook*. Edinburgh: Scottish Intercollegiate Guidelines Network; 2011.
- Helander A, Jaeken J, Matthijs G, Eggertsen G. Asymptomatic phosphomannose isomerase deficiency (MPI-CDG) initially mistaken for excessive alcohol consumption. *Clin Chim Acta*. 2014;431:15-18.
- Deeb A, Al Amoodi A. A novel homozygous mutation in the mannose phosphate isomerase gene causing congenital disorder of glycation and hyperinsulinemic hypoglycemia in an infant. *Clin Case Rep*. 2018;6(3):479-483.
- Damen G, de Klerk H, Huijman J, den Hollander J, Sinaasappel M. Gastrointestinal and other clinical manifestations in 17 children with congenital disorders of glycosylation type Ia, Ib, and Ic. *J Pediatr Gastroenterol Nutr*. 2004;38(3): 282-287.
- Jaeken J, Matthijs G, Saudubray JM, et al. Phosphomannose isomerase deficiency: a carbohydrate-deficient glycoprotein syndrome with hepatic-intestinal presentation. *Am J Hum Genet*. 1998;62(6):1535-1539.
- Marques-da-Silva D, Dos Reis FV, Monticelli M, et al. Liver involvement in congenital disorders of glycosylation (CDG). A systematic review of the literature. *J Inherit Metab Dis*. 2017;40 (2):195-207.
- Witters P, Cassiman D, Morava E. Nutritional therapies in congenital disorders of glycosylation (CDG). *Nutrients*. 2017;9(11): E1222. <https://doi.org/10.3390/nu9111222>.
- de Lonlay P, Cuer M, Vuillaumier-Barrot S, et al. Hyperinsulinemic hypoglycemia as a presenting sign in phosphomannose isomerase deficiency: a new manifestation of carbohydrate-deficient glycoprotein syndrome treatable with mannose. *J Pediatr*. 1999;135(3):379-383.
- Janssen MC, de Kleine RH, van den Berg AP, et al. Successful liver transplantation and long-term follow-up in a patient with MPI-CDG. *Pediatrics*. 2014;134(1):e279-e283.

34. Liem YS, Bode L, Freeze HH, Leebeek FW, Zandbergen AA, Paul Wilson J. Using heparin therapy to reverse protein-losing enteropathy in a patient with CDG-Ib. *Nat Clin Pract Gastroenterol Hepatol.* 2008;5(4):220-224.
35. van Diggelen OP, Maat-Kievit J, de Klerk JBC, et al. Two more Dutch cases of CDG syndrome 1b: phosphomannose isomerase deficiency. *J Inherit Metab Dis.* 1998;21(Suppl 2):97.
36. Westphal V, Kjaergaard S, Davis JA, Peterson SM, Skovby F, Freeze HH. Genetic and metabolic analysis of the first adult with congenital disorder of glycosylation type Ib: long-term outcome and effects of mannose supplementation. *Mol Genet Metab.* 2001;73(1):77-85.
37. Babovic-Vuksanovic D, Patterson MC, Schwenk WF, et al. Severe hypoglycemia as a presenting symptom of carbohydrate-deficient glycoprotein syndrome. *J Pediatr.* 1999;135(6):775-781.
38. Penel-Capelle D, Dobbelaere D, Jaeken J, Klein A, Cartigny M, Weill J. Congenital disorder of glycosylation Ib (CDG-Ib) without gastrointestinal symptoms. *J Inherit Metab Dis.* 2003;26(1):83-85.
39. Adamowicz M, Matthijs G, van Schaftingen E, et al. New case of phosphomannose isomerase deficiency (CDG 1b). *J Inherit Metab Dis.* 2000;23(Suppl 1):184.
40. de Koning TJ, Dorland L, van Diggelen OP, et al. A novel disorder of N-glycosylation due to phosphomannose isomerase deficiency. *Biochem Biophys Res Commun.* 1998;245(1):38-42.
41. de Koning TJ, Nikkels PG, Dorland L, et al. Congenital hepatic fibrosis in 3 siblings with phosphomannose isomerase deficiency. *Virchows Arch.* 2000;437(1):101-105.
42. de Lonlay P, Seta N, Barrot S, et al. A broad spectrum of clinical presentations in congenital disorders of glycosylation I: a series of 26 cases. *J Med Genet.* 2001;38(1):14-19.
43. Hendriksz CJ, McClean P, Henderson MJ, et al. Successful treatment of carbohydrate deficient glycoprotein syndrome type 1b with oral mannose. *Arch Dis Child.* 2001;85(4):339-340.
44. Iancu TC, Mahajnah M, Manov I, Cherurg S, Knopf C, Mandel H. The liver in congenital disorders of glycosylation: ultrastructural features. *Ultrastruct Pathol.* 2007;31(3):189-197.
45. Kelly DF, Boneh A, Pitsch S, et al. Carbohydrate-deficient glycoprotein syndrome 1b: a new answer to an old diagnostic dilemma. *J Paediatr Child Health.* 2001;37(5):510-512.
46. Mention K, Lacaille F, Valayannopoulos V, et al. Development of liver disease despite mannose treatment in two patients with CDG-Ib. *Mol Genet Metab.* 2008;93(1):40-43.
47. Schwarzenberg SJ. Congenital hepatic fibrosis-is it really a matter of "a spoonful of sugar?". *Hepatology.* 1999;30(2):582-583.
48. Zentilin Boyer M, de Lonlay P, Seta N, et al. Failure to thrive and intestinal diseases in congenital disorders of glycosylation. *Arch Pediatr.* 2003;10(7):590-595.
49. de la Morena-Barrio ME, Wypasek E, Owczarek D, et al. MPI-CDG with transient hypoglycosylation and antithrombin deficiency. *Haematologica.* 2019;104(2):e79-e82.
50. Martin Hernandez E, Vega Pajares AI, Perez Gonzalez B, et al. Congenital disorder of glycosylation type 1b. Experience with mannose treatment. *An Pediatr (Barc).* 2008;69(4):358-365.
51. Oren A, Houwen RH. Phosphomannoseisomerase deficiency as the cause of protein-losing enteropathy and congenital liver fibrosis. *J Pediatr Gastroenterol Nutr.* 1999;29(2):231-232.
52. Herfarth H, Hofstadter F, Feuerbach S, Jurgen Schlitt H, Scholmerich J, Rogler G. A case of recurrent gastrointestinal bleeding and protein-losing gastroenteropathy. *Nat Clin Pract Gastroenterol Hepatol.* 2007;4(5):288-293.
53. Bode L, Eklund EA, Murch S, Freeze HH. Heparan sulfate depletion amplifies TNF-alpha-induced protein leakage in an in vitro model of protein-losing enteropathy. *Am J Physiol Gastrointest Liver Physiol.* 2005;288(5):G1015-G1023.
54. Bode L, Freeze HH. Applied glycoproteomics—approaches to study genetic-environmental collisions causing protein-losing enteropathy. *Biochim Biophys Acta.* 2006;1760(4):547-559.
55. Bode L, Murch S, Freeze HH. Heparan sulfate plays a central role in a dynamic in vitro model of protein-losing enteropathy. *J Biol Chem.* 2006;281(12):7809-7815.
56. Ackermann AM, Freeze HH, Ficicioglu C, Kaestner KH, Stanley CA. Hypoglycemia due to lower threshold of glucose-stimulated insulin secretion in phosphoglucomutase 1 deficiency. Annual Meeting of the Pediatric Academic Societies: (2015). April 25-28, 2015; San Diego, CA.
57. Wong SY, Beamer LJ, Gadomski T, et al. Defining the phenotype and assessing severity in phosphoglucomutase-1 deficiency. *J Pediatr.* 2016;175(130-6):e8.
58. Zeevaert R, Scalais E, Muino Mosquera L, et al. PGM1 deficiency diagnosed during an endocrine work-up of low IGF-1 mediated growth failure. *Acta Clin Belg.* 2016;71(6):435-437.
59. Bohles H, Sewell AA, Gebhardt B, Reinecke-Luthge A, Kloppel G, Marquardt T. Hyperinsulinaemic hypoglycaemia—leading symptom in a patient with congenital disorder of glycosylation Ia (phosphomannomutase deficiency). *J Inherit Metab Dis.* 2001;24(8):858-862.
60. Jain V, Menon RK. Disorders of carbohydrate metabolism. In: Gleason CJS, ed. *Avery's Diseases of the Newborn.* 9th ed. Philadelphia, PA: Elsevier; 2018:1320-1329.
61. Cabezas OR, Flanagan SE, Stanescu H, et al. Polycystic kidney disease with hyperinsulinemic hypoglycemia caused by a promoter mutation in phosphomannomutase 2. *JASN.* 2017;28(8):2529-2539.
62. Miller BS, Khosravi MJ, Patterson MC, Conover CA. IGF system in children with congenital disorders of glycosylation. *Clin Endocrinol (Oxf).* 2009;70(6):892-897.
63. Thornton PS, Stanley CA, De Leon DD, et al. Recommendations from the pediatric endocrine society for evaluation and management of persistent hypoglycemia in neonates, infants, and children. *J Pediatr.* 2015;167(2):238-245.
64. Yorifuji T, Horikawa R, Hasegawa T, et al. Clinical practice guidelines for congenital hyperinsulinism. *Clin Pediatr Endocrinol.* 2017;26(3):127-152.
65. Tamminga RY, Lefeber DJ, Kamps WA, van Spronsen FJ. Recurrent thrombo-embolism in a child with a congenital disorder of glycosylation (CDG) type Ib and treatment with mannose. *Pediatr Hematol Oncol.* 2008;25(8):762-768.
66. Van Geet C, Jaeken J. A unique pattern of coagulation abnormalities in carbohydrate-deficient glycoprotein syndrome. *Pediatr Res.* 1993;33(5):540-541.
67. Young G, Driscoll MC. Coagulation abnormalities in the carbohydrate-deficient glycoprotein syndrome: case report and review of the literature. *Am J Hematol.* 1999;60(1):66-69.
68. Van Geet C, Jaeken J, Freson K, et al. Congenital disorders of glycosylation type Ia and IIa are associated with different primary haemostatic complications. *J Inherit Metab Dis.* 2001;24(4):477-492.

69. Kearon C, Akl EA, Ornelas J, et al. Antithrombotic therapy for VTE disease: CHEST guideline and expert panel report. *Chest*. 2016;149(2):315-352.
70. Monagle P, Chan AKC, Goldenberg NA, et al. Antithrombotic therapy in neonates and children: antithrombotic therapy and prevention of thrombosis, 9th ed: American College of Chest Physicians Evidence-Based Clinical Practice Guidelines. *Chest*. 2012;141(2 suppl):e737S-e801S.
71. Meaudre E, Meyrieux V, Suprano I, Camboulives J, Paut O. Anesthesia considerations in carbohydrate-deficient glycoprotein syndrome type I. *Paediatr Anaesth*. 2005;15(10):905-906.
72. Freeze HH. New diagnosis and treatment of congenital hepatic fibrosis. *J Pediatr Gastroenterol Nutr*. 1999;29(1):104-106.
73. Hertz-Pannier L, Dechaux M, Sinico M, et al. Congenital disorders of glycosylation type I: a rare but new cause of hypercholechoic kidneys in infants and children due to early microcystic changes. *Pediatr Radiol*. 2006;36(2):108-114.
74. Barone R, Fiumara A, Jaeken J. Congenital disorders of glycosylation with emphasis on cerebellar involvement. *Semin Neurol*. 2014;34(3):357-366.
75. Jaeken J, van Eijk HG, van der Heul C, Corbeel L, Eeckels R, Eggermont E. Sialic acid-deficient serum and cerebrospinal fluid transferrin in a newly recognized genetic syndrome. *Clin Chim Acta*. 1984;144(2-3):245-247.
76. Aoki H, Shiomi M, Ikeda T, et al. Decreased sialylation of IgA1 O-glycans associated with pneumococcal hemolytic uremic syndrome. *Pediatr Int*. 2013;55(6):e143-e145.
77. Zuhlsdorf A, Park JH, Wada Y, et al. Transferrin variants: pitfalls in the diagnostics of congenital disorders of glycosylation. *Clin Biochem*. 2015;48(1-2):11-13.
78. Jaeken J, Lefeber D, Matthijs G. Clinical utility gene card for: phosphomannose isomerase deficiency. *Eur J Hum Genet*. 2014;22(9):e1-e3. <https://doi.org/10.1038/ejhg.2014.29>.
79. Helander A, Bergstrom J, Freeze HH. Testing for congenital disorders of glycosylation by HPLC measurement of serum transferrin glycoforms. *Clin Chem*. 2004;50(5):954-958.
80. Parente F, Ah Mew N, Jaeken J, Gilfix BM. A new capillary zone electrophoresis method for the screening of congenital disorders of glycosylation (CDG). *Clin Chim Acta*. 2010;411(1-2):64-66.
81. Quintana E, Montero R, Casado M, et al. Comparison between high performance liquid chromatography and capillary zone electrophoresis for the diagnosis of congenital disorders of glycosylation. *J Chromatogr B Analyt Technol Biomed Life Sci*. 2009;877(24):2513-2518.
82. Schollen E, Martens K, Geuzens E, Matthijs G. DHPLC analysis as a platform for molecular diagnosis of congenital disorders of glycosylation (CDG). *Eur J Hum Genet*. 2002;10(10):643-648.
83. Helander A, Wielders J, Anton R, et al. Standardisation and use of the alcohol biomarker carbohydrate-deficient transferrin (CDT). *Clin Chim Acta*. 2016;459:19-24.
84. Seta N, Barnier A, Hochedez F, Besnard MA, Durand G. Diagnostic value of Western blotting in carbohydrate-deficient glycoprotein syndrome. *Clin Chim Acta*. 1996;254(2):131-140.
85. Mills K, Mills P, Jackson M, et al. Diagnosis of congenital disorders of glycosylation type-I using protein chip technology. *Proteomics*. 2006;6(7):2295-2304.
86. van Scherpenzeel M, Steenbergen G, Morava E, Wevers RA, Lefeber DJ. High-resolution mass spectrometry glycoprofiling of intact transferrin for diagnosis and subtype identification in the congenital disorders of glycosylation. *Transl Res*. 2015;166(6):639-649. e1.
87. He P, Ng BG, Losfeld ME, Zhu W, Freeze HH. Identification of intercellular cell adhesion molecule 1 (ICAM-1) as a hypoglycosylation marker in congenital disorders of glycosylation cells. *J Biol Chem*. 2012;287(22):18210-18217.
88. He P, Srikrishna G, Freeze HH. N-glycosylation deficiency reduces ICAM-1 induction and impairs inflammatory response. *Glycobiology*. 2014;24(4):392-398.
89. Jackson M, Clayton P, Grunewald S, et al. Elevation of plasma aspartylglucosaminidase is a useful marker for the congenital disorders of glycosylation type I (CDG I). *J Inher Metab Dis*. 2005;28(6):1197-1198.
90. Zhang W, James PM, Ng BG, et al. A novel N-yetrasaccharide in patients with congenital disorders of glycosylation, including asparagine-linked glycosylation protein 1, phosphomannomutase 2, and mannose phosphate isomerase deficiencies. *Clin Chem*. 2016;62(1):208-217.
91. Li Y, Ogata Y, Freeze HH, Scott CR, Turecek F, Gelb MH. Affinity capture and elution/electrospray ionization mass spectrometry assay of phosphomannomutase and phosphomannose isomerase for the multiplex analysis of congenital disorders of glycosylation types Ia and Ib. *Anal Chem*. 2003;75(1):42-48.
92. Van Schaftingen E, Jaeken J. Phosphomannomutase deficiency is a cause of carbohydrate-deficient glycoprotein syndrome type I. *FEBS Lett*. 1995;377(3):318-320.
93. Cleasby A, Wonacott A, Skarzynski T, et al. The x-ray crystal structure of phosphomannose isomerase from *Candida albicans* at 1.7 angstrom resolution. *Nat Struct Biol*. 1996;3(5):470-479.
94. Haeuptle MA, Hennet T. Congenital disorders of glycosylation: an update on defects affecting the biosynthesis of dolichol-linked oligosaccharides. *Hum Mutat*. 2009;30(12):1628-1641.
95. Vuillaumier-Barrot S, Isidor B, Dupre T, Le Bizec C, David A, Seta N. Expanding the Spectrum of PMM2-CDG phenotype. *JIMD Rep*. 2012;5:123-125.
96. Brasil S, Pascoal C, Francisco R, et al. CDG therapies: from bench to bedside. *Int J Mol Sci*. 2018;19(5). <https://doi.org/10.3390/ijms19051304>
97. de Koning TJ, Dorland L, van Berge Henegouwen GP. Phosphomannose isomerase deficiency as a cause of congenital hepatic fibrosis and protein-losing enteropathy. *J Hepatol*. 1999;31(3):557-560.
98. Etchison JR, Freeze HH. Enzymatic assay of D-mannose in serum. *Clin Chem*. 1997;43(3):533-538.

SUPPORTING INFORMATION

Additional supporting information may be found online in the Supporting Information section at the end of this article.

How to cite this article: Čechová A, Altassan R, Borgel D, et al. Consensus guideline for the diagnosis and management of mannose phosphate isomerase-congenital disorder of glycosylation. *J Inher Metab Dis*. 2020;1–23. <https://doi.org/10.1002/jimd.12241>